A 34-year-old man is hospitalized due to trauma sustained during a motor vehicle collision. He subsequently develops worsening shortness of breath and confusion and dies despite appropriate management. Autopsy examination shows scattered petechiae on the anterior thorax. Microscopic evaluation of his pulmonary vessels reveals the findings shown below.

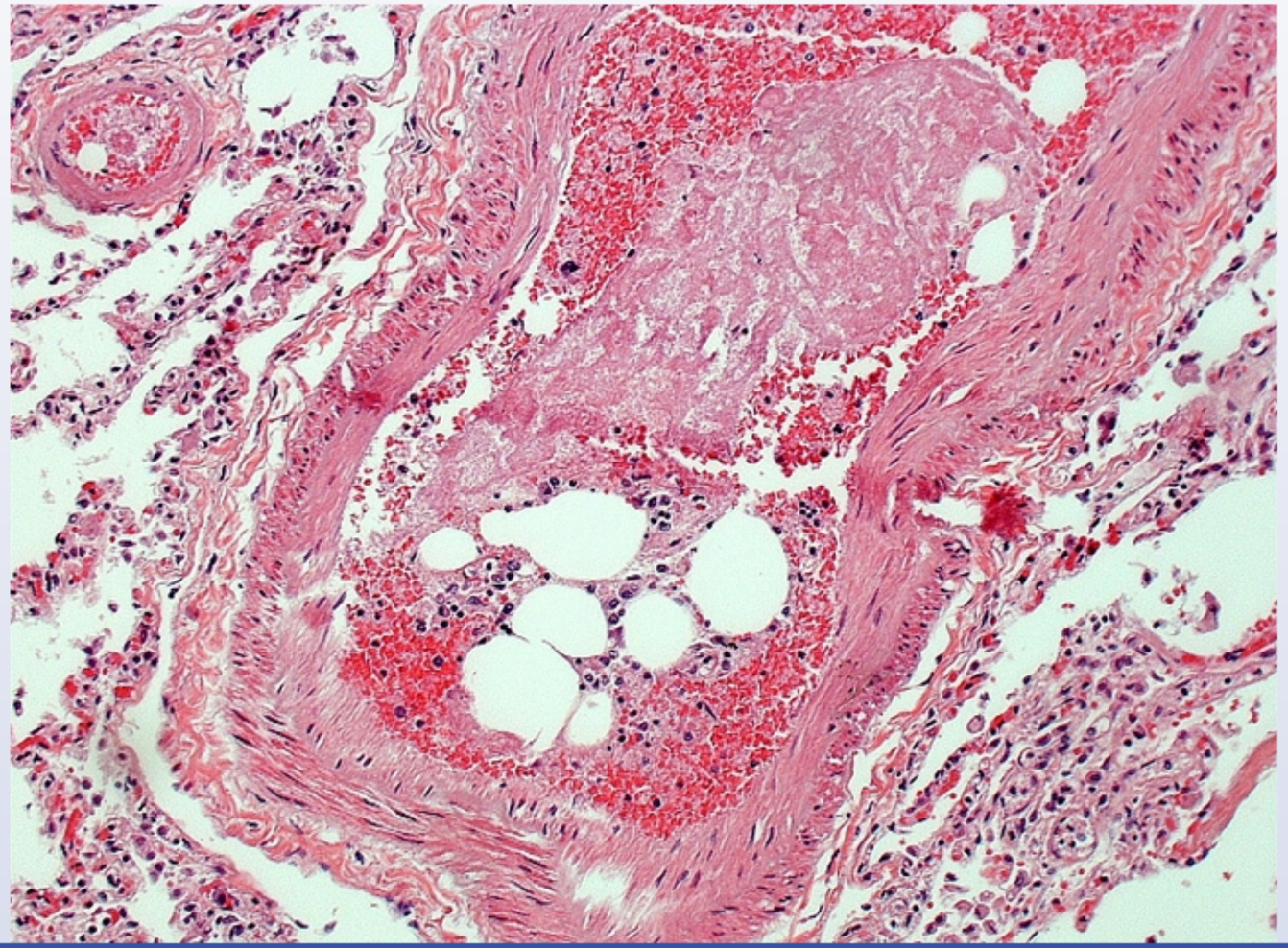

Settings

1
2
3
4
5
6
7
8
9
10
11
12
13
14
15
16
17
18

Item 1 of 18
Question Id: 197

Mark | Previous | Next | Full Screen | Tutorial | Lab Values | Notes | Calculator | Reverse Color | Text Zoom | Settings

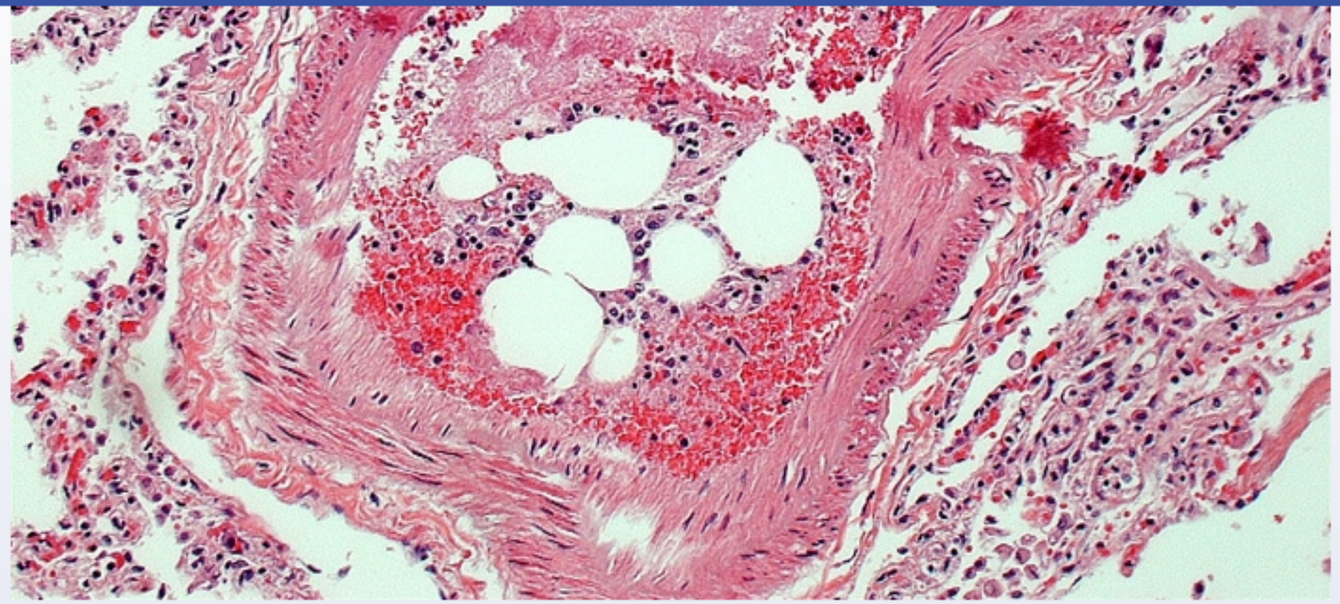

Which of the following most likely predisposed this patient to developing the observed histopathologic abnormality?

- A. Aspiration of gastric contents
- B. Left ventricular dysfunction
- C. Long-bone fracture
- D. Severe systemic infection
- E. Thrombosis in the deep veins

Submit

Block Time Remaining: 00:00:06
TUTOR

8 | Feedback | Suspend | End Block

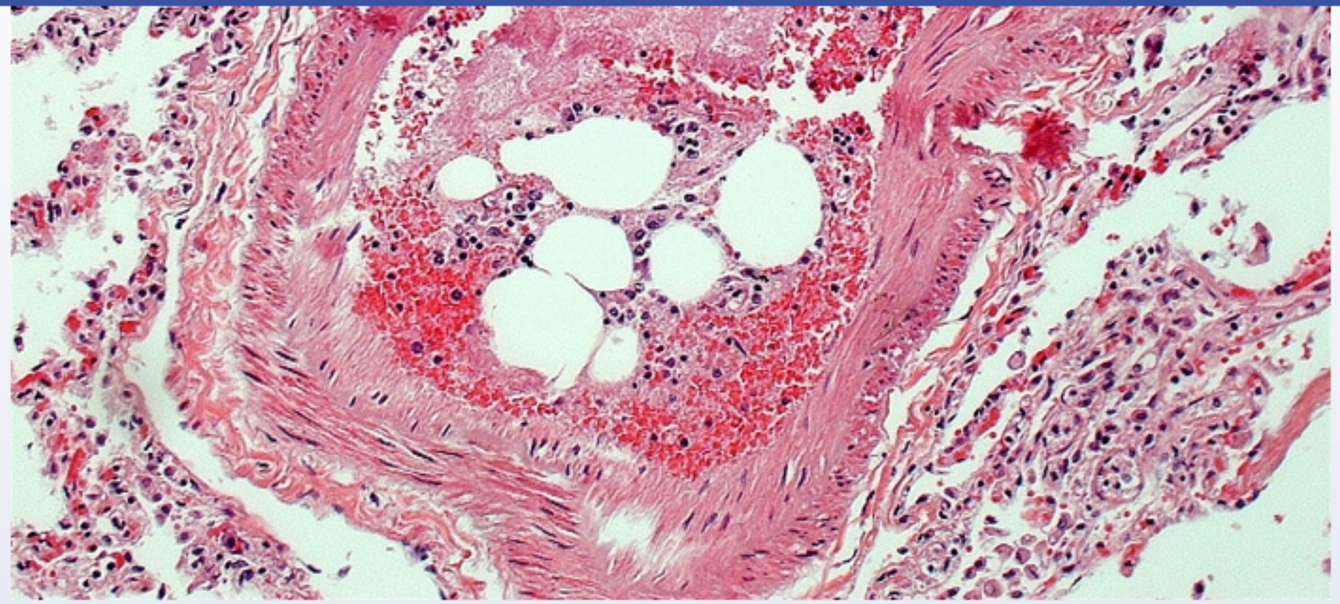

Which of the following most likely predisposed this patient to developing the observed histopathologic abnormality?

- A. Aspiration of gastric contents (1%)
- B. Left ventricular dysfunction (2%)
- ✓ C. Long-bone fracture (86%)
- D. Severe systemic infection (2%)
- E. Thrombosis in the deep veins (7%)

Omitted
Correct answer

86%
Answered correctly

07 secs
Time Spent

05/23/2020
Last Updated

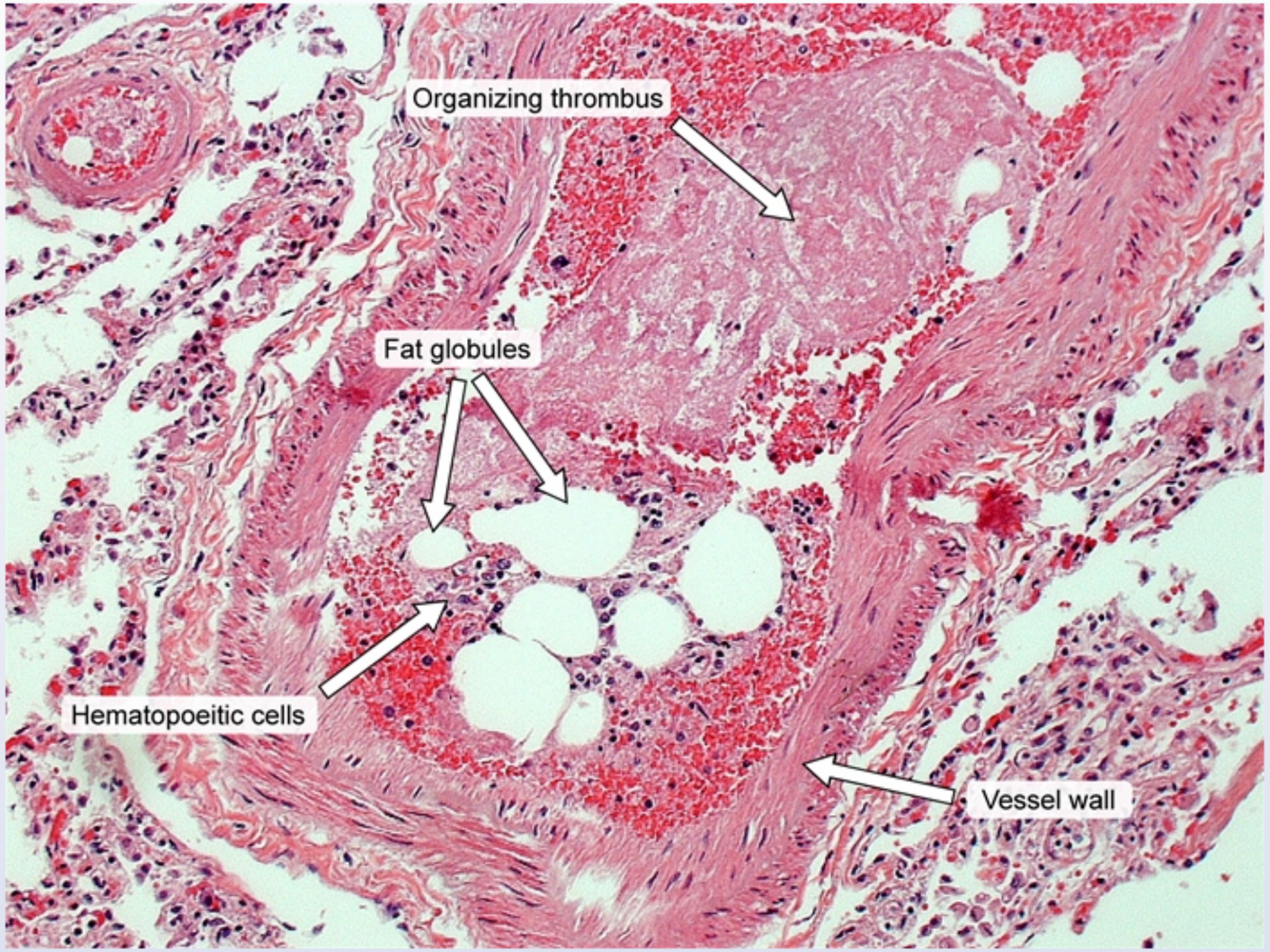

The histologic section of this patient's lung shows an aggregate of fat globules, hematopoietic cells, and organizing thrombus lodged inside the pulmonary vasculature. This is consistent with bone marrow embolism, which occurs in **fat embolism syndrome** (FES).

FES classically presents with the triad of **respiratory distress**, **neurologic impairment**, and **petechial rash** within **24-72 hours** following a **long-**

The histologic section of this patient's lung shows an aggregate of fat globules, hematopoietic cells, and organizing thrombus lodged inside the pulmonary vasculature. This is consistent with bone marrow embolism, which occurs in **fat embolism syndrome** (FES).

FES classically presents with the triad of **respiratory distress**, **neurologic impairment**, and **petechial rash** within **24-72 hours** following a **long-bone or pelvic fracture**. Severe skeletal injuries can cause fat globules to be dislodged from bone marrow into the bloodstream, where they form aggregates with platelets and red blood cells. These aggregates occlude pulmonary microvessels and impair gas exchange. Some fat emboli may be small enough to pass through the pulmonary circulation and cause microvascular occlusion in the systemic circulation, leading to the neurologic manifestations (eg, confusion) and petechial rash characterizing the condition. Release of toxic inflammatory mediators (eg, cytokines, free fatty acids) may contribute to the neurologic manifestations and rash. Thrombocytopenia may also occur due to platelet adherence and aggregation to circulating fat globules.

(Choice A) Aspiration of gastric contents can lead to aspiration pneumonitis or aspiration pneumonia. The lung parenchyma demonstrates macrophage-rich giant cells and fibromyxoid connective tissue.

(Choice B) Left ventricular dysfunction can lead to heart failure and pulmonary edema. Over time, alveolar fibrosis develops and there is accumulation of hemosiderin-laden macrophages, also known as heart failure cells.

(Choice D) Severe systemic infection, or sepsis, can lead to acute respiratory distress syndrome, in which parenchymal inflammation leads to accumulation of interstitial fluid and fluid leakage in the alveoli. Histopathology often shows diffuse alveolar damage.

(Choice E) Thrombosis in the deep veins can lead to acute pulmonary embolism. Due to localized ischemia, the adjacent lung parenchyma can demonstrate coagulative necrosis and hemorrhage.

Educational objective:
Fat embolism syndrome most commonly results from the release of fat globules from bone marrow following a long-bone or pelvic fracture. The fat globules form inflammatory aggregates that cause microvessel obstruction and systemic inflammation leading to the triad of respiratory distress, neurologic dysfunction, and petechial rash that characterizes the condition.

Pathology Pulmonary & Critical Care Fat embolism

FES classically presents with the triad of **respiratory distress**, **neurologic impairment**, and **petechial rash** within **24-72 hours** following a **long-bone or pelvic fracture**. Severe skeletal injuries can cause fat globules to be dislodged from bone marrow into the bloodstream, where they form aggregates with platelets and red blood cells. These aggregates occlude pulmonary microvessels and impair gas exchange. Some fat emboli may be small enough to pass through the pulmonary circulation and cause microvascular occlusion in the systemic circulation, leading to the neurologic manifestations (eg, confusion) and petechial rash characterizing the condition. Release of toxic inflammatory mediators (eg, cytokines, free fatty acids) may contribute to the neurologic manifestations and rash. Thrombocytopenia may also occur due to platelet adherence and aggregation to circulating fat globules.

(Choice A) Aspiration of gastric contents can lead to aspiration pneumonitis or aspiration pneumonia. The lung parenchyma demonstrates macrophage-rich giant cells and fibromyxoid connective tissue.

(Choice B) Left ventricular dysfunction can lead to heart failure and pulmonary edema. Over time, alveolar fibrosis develops and there is accumulation of hemosiderin-laden macrophages, also known as heart failure cells.

(Choice D) Severe systemic infection, or sepsis, can lead to acute respiratory distress syndrome, in which parenchymal inflammation leads to accumulation of interstitial fluid and fluid leakage in the alveoli. Histopathology often shows diffuse alveolar damage.

(Choice E) Thrombosis in the deep veins can lead to acute pulmonary embolism. Due to localized ischemia, the adjacent lung parenchyma can demonstrate coagulative necrosis and hemorrhage.

Educational objective:
Fat embolism syndrome most commonly results from the release of fat globules from bone marrow following a long-bone or pelvic fracture. The fat globules form inflammatory aggregates that cause microvessel obstruction and systemic inflammation leading to the triad of respiratory distress, neurologic dysfunction, and petechial rash that characterizes the condition.

Pathology	Pulmonary & Critical Care	Fat embolism
Subject	System	Topic

Copyright © UWorld. All rights reserved.

Settings

1
2
3
4
5
6
7
8
9
10
11
12
13
14
15
16
17
18

Item 1 of 18
Question Id: 197

Mark | Previous | Next | Full Screen | Tutorial | Lab Values | Notes | Calculator | Reverse Color | Text Zoom | Settings

FES classically presents with the triad of **respiratory distress**, **neurologic impairment**, and **petechial rash** within **24-72 hours** following a **long-**

Exhibit Display

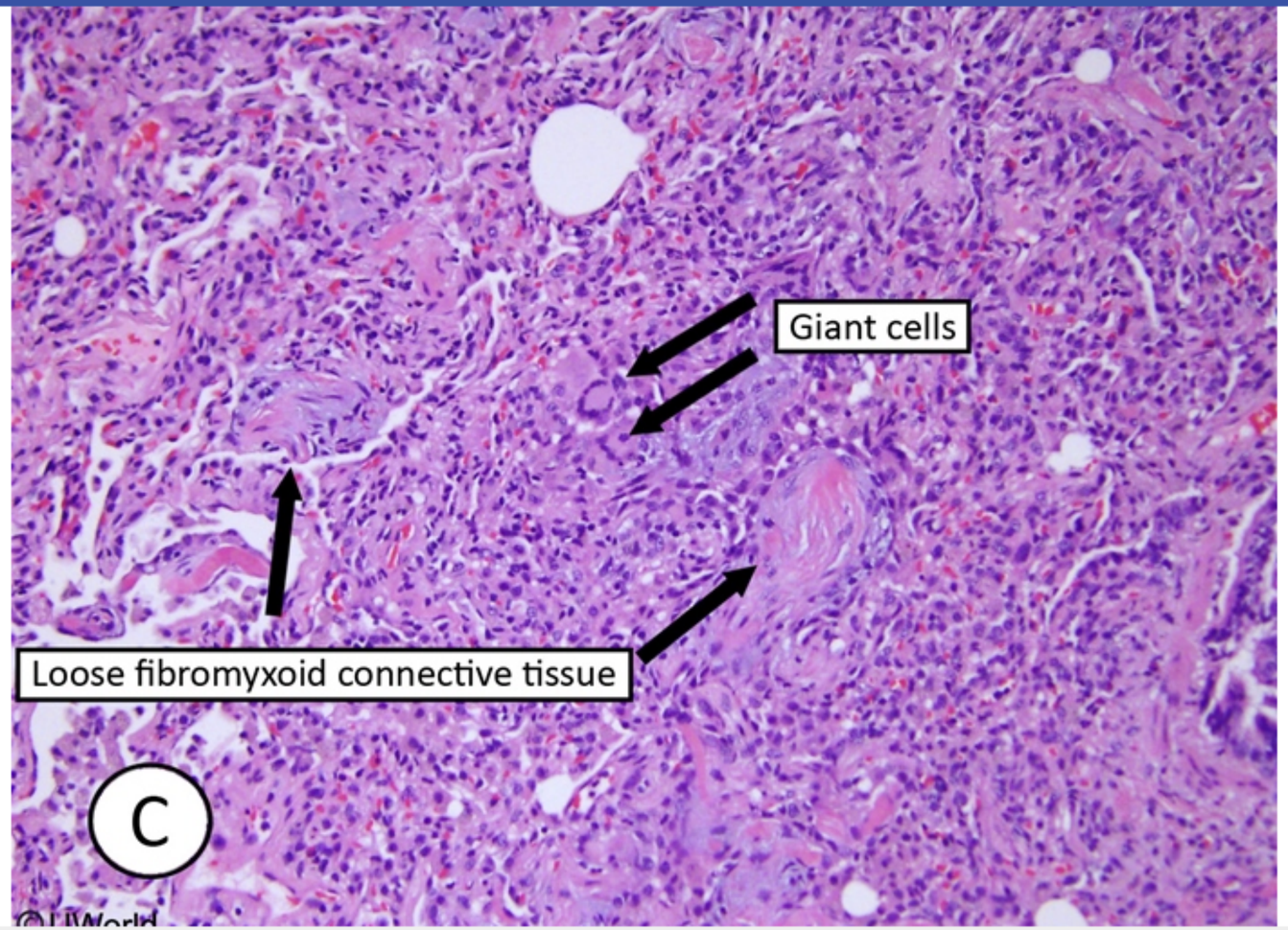

Zoom In | Zoom Out | Reset | Add To New Card | Existing Card

Block Time Remaining: 00:00:07
TUTOR

8 | Feedback | Suspend | End Block

Settings

1
2
3
4
5
6
7
8
9
10
11
12
13
14
15
16
17
18

Item 1 of 18
Question Id: 197

Mark | Previous | Next | Full Screen | Tutorial | Lab Values | Notes | Calculator | Reverse Color | Text Zoom | Settings

FES classically presents with the triad of **respiratory distress**, **neurologic impairment**, and **petechial rash** within **24-72 hours** following a **long-**

Exhibit Display

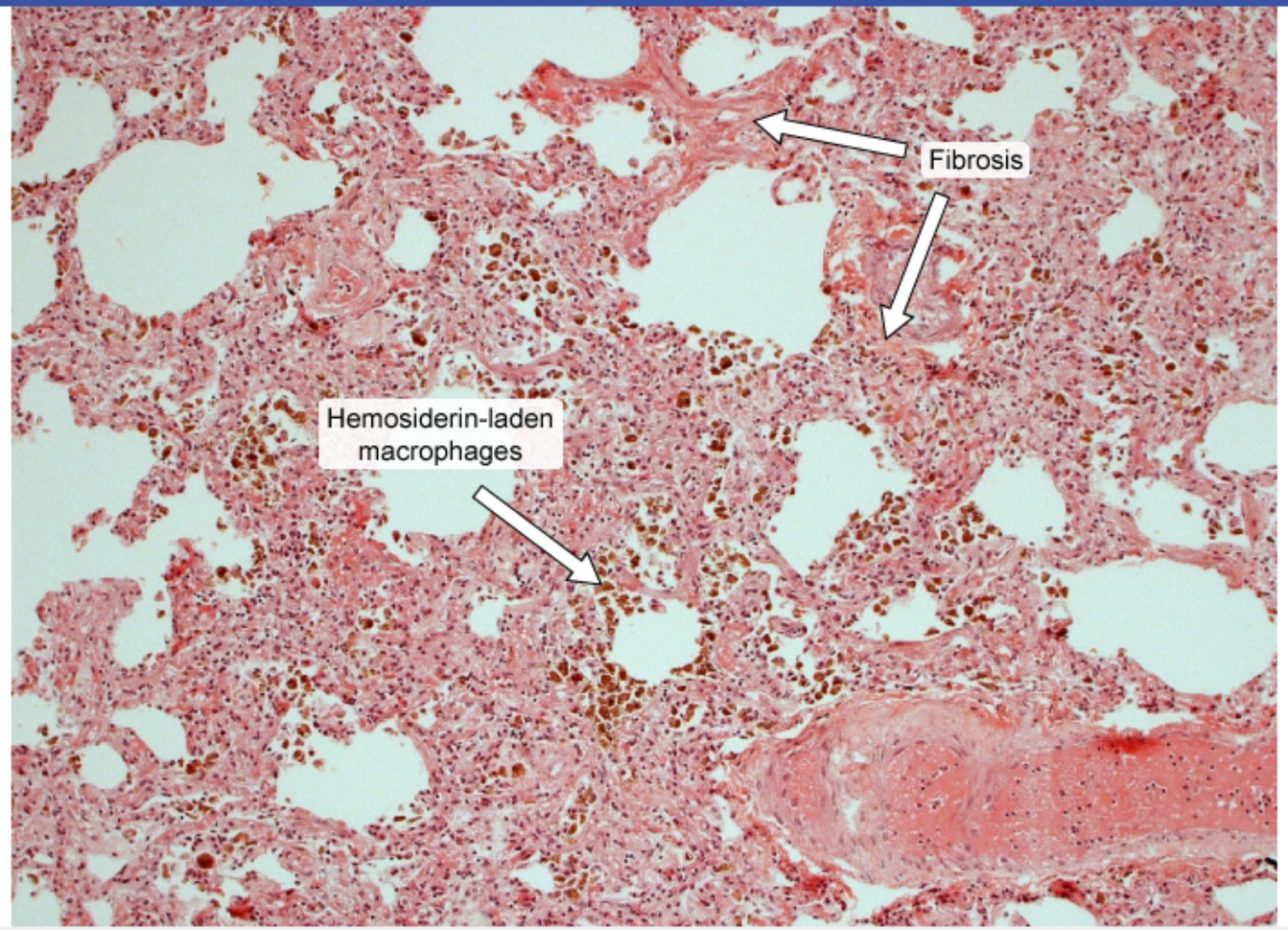

Zoom In | Zoom Out | Reset | Add To New Card | Existing Card

Block Time Remaining: 00:00:07
TUTOR

8 | Feedback | Suspend | End Block

Settings

1
2
3
4
5
6
7
8
9
10
11
12
13
14
15
16
17
18

Item 1 of 18
Question Id: 197

Mark | Previous | Next | Full Screen | Tutorial | Lab Values | Notes | Calculator | Reverse Color | Text Zoom | Settings

FES classically presents with the triad of **respiratory distress**, **neurologic impairment**, and **petechial rash** within **24-72 hours** following a **long-**

Exhibit Display

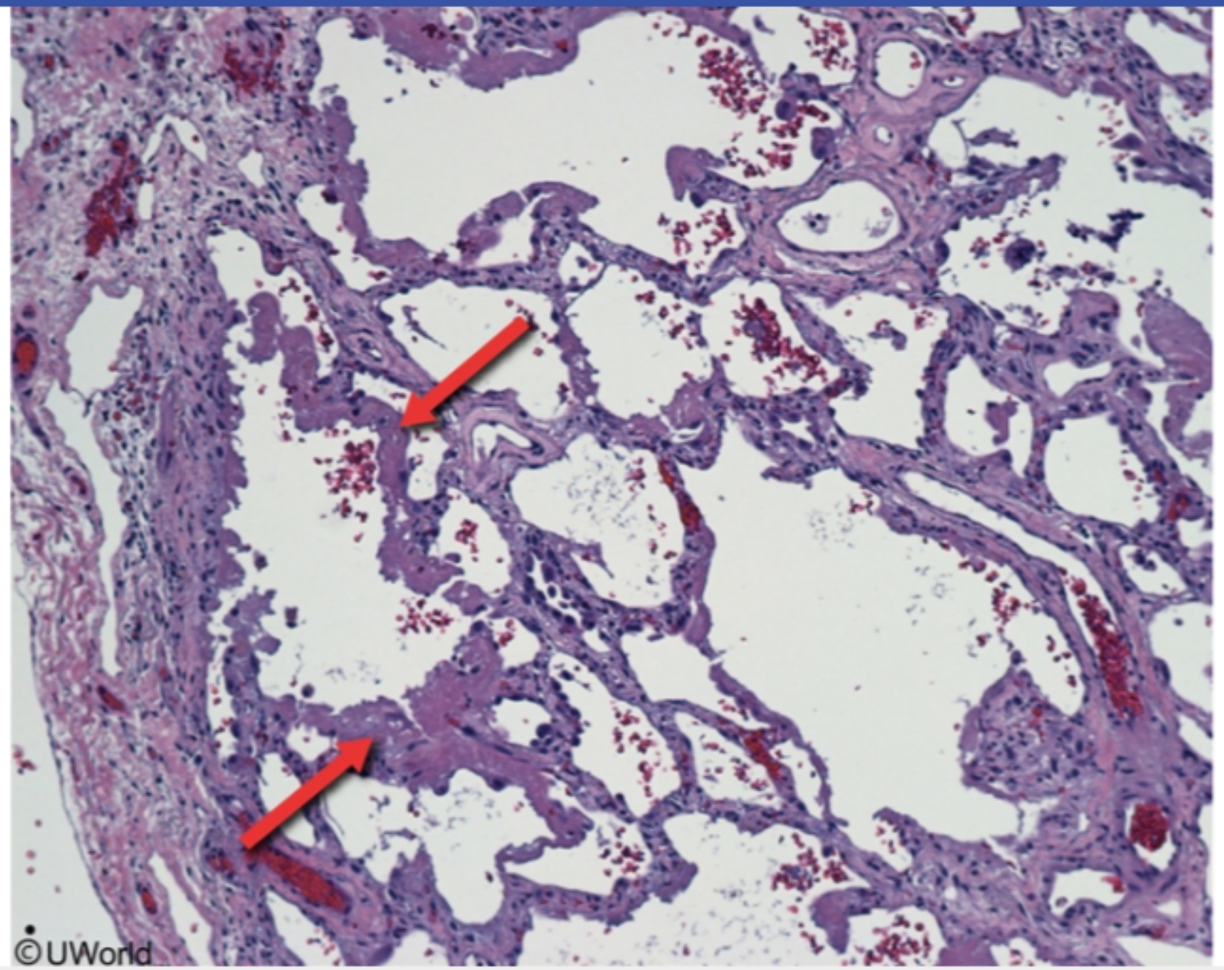

Zoom In | Zoom Out | Reset | Add To New Card | Existing Card

Block Time Remaining: 00:00:07
TUTOR

8 | Feedback | Suspend | End Block

Settings

1
2
3
4
5
6
7
8
9
10
11
12
13
14
15
16
17
18

Item 1 of 18
Question Id: 197

Mark | Previous | Next | Full Screen | Tutorial | Lab Values | Notes | Calculator | Reverse Color | Text Zoom | Settings

FES classically presents with the triad of **respiratory distress**, **neurologic impairment**, and **petechial rash** within **24-72 hours** following a **long-**

Exhibit Display

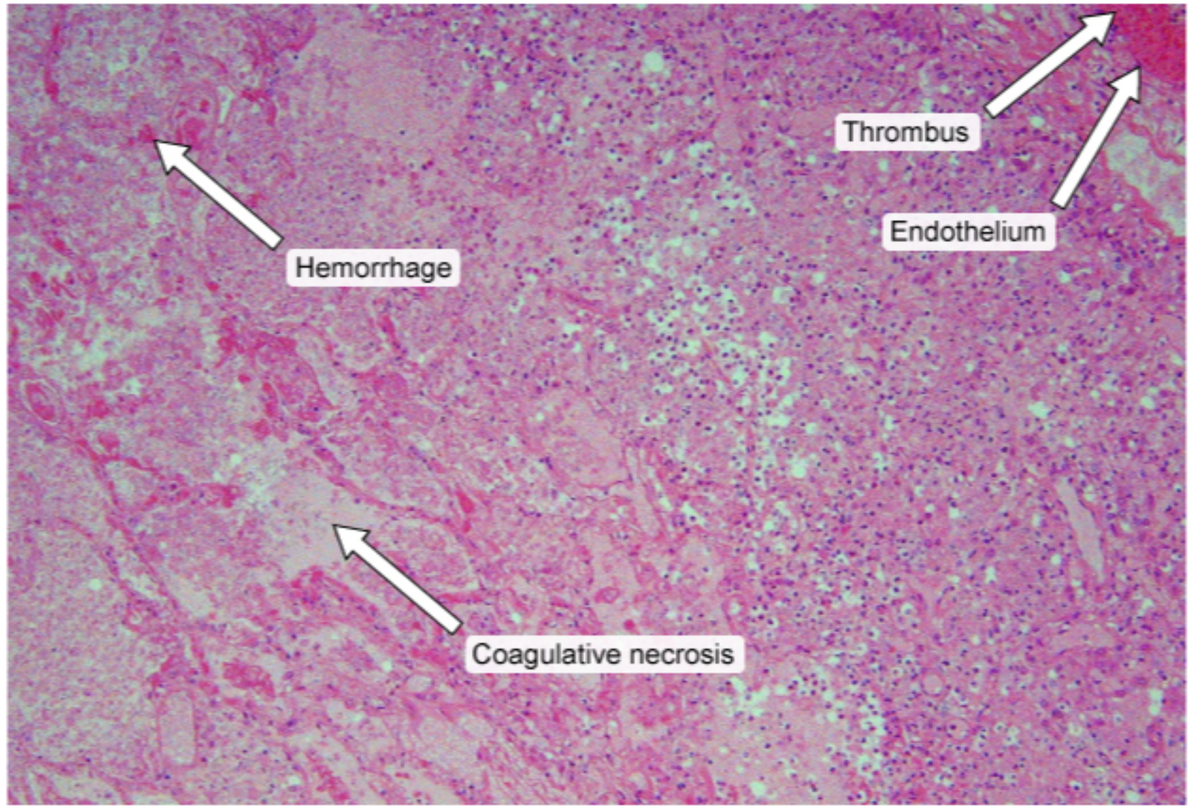

Zoom In | Zoom Out | Reset | Add To New Card | Existing Card

Block Time Remaining: 00:00:07
TUTOR

8 | Feedback | Suspend | End Block

The following vignette applies to the next **2** items. The items in the set must be answered in sequential order. Once you click **Proceed to Next Item**, you will not be able to add or change an answer.

An 87-year-old nursing home resident is brought to the emergency department with a 2-day history of fever, vomiting, and progressive lethargy. The patient's past medical history is significant for advanced dementia and stroke. Temperature is 38.3 C (101 F), blood pressure is 88/62 mm Hg, and pulse is 120/min and regular. On examination, he is lethargic but arousable. Coarse rhonchi are heard over the right midlung. Laboratory results are as follows:

Leukocytes	23,000/mm^3
Platelets	210,000/mm^3
Sodium	140 mEq/L
Potassium	4.2 mEq/L
Chloride	101 mEq/L
Bicarbonate	18 mEq/L
Creatinine	0.9 mg/dL
Glucose	121 mg/dL
Lactic acid	4.0 mmol/L (normal, <2 mmol/L)

Item 1 of 2

Which of the following is the most likely cause of this patient's increased anion gap?

A. Decreased oxidative phosphorylation

Sodium	140 mEq/L
Potassium	4.2 mEq/L
Chloride	101 mEq/L
Bicarbonate	18 mEq/L
Creatinine	0.9 mg/dL
Glucose	121 mg/dL
Lactic acid	4.0 mmol/L (normal, <2 mmol/L)

Item 1 of 2

Which of the following is the most likely cause of this patient's increased anion gap?

- A. Decreased oxidative phosphorylation
- B. Impaired hepatic gluconeogenesis
- C. Impaired renal tubular bicarbonate reabsorption
- D. Increased lipolysis and ketogenesis
- E. Increased protein breakdown

Submit

Sodium	140 mEq/L
Potassium	4.2 mEq/L
Chloride	101 mEq/L
Bicarbonate	18 mEq/L
Creatinine	0.9 mg/dL
Glucose	121 mg/dL
Lactic acid	4.0 mmol/L (normal, <2 mmol/L)

Item 1 of 2

Which of the following is the most likely cause of this patient's increased anion gap?

- ✓ A. Decreased oxidative phosphorylation (47%)
- B. Impaired hepatic gluconeogenesis (5%)
- C. Impaired renal tubular bicarbonate reabsorption (17%)
- D. Increased lipolysis and ketogenesis (20%)
- E. Increased protein breakdown (8%)

Omitted
Correct answer

47%
Answered correctly

04 secs
Time Spent

03/01/2020
Last Updated

Causes of lactic acidosis	
Underlying mechanism	**Etiology**
Enhanced metabolic rate	• Seizures • Exercise
Reduced oxygen delivery	• Cardiac or pulmonary failure • Tissue ischemia/infarction
Diminished lactate catabolism	• Hepatic failure or hypoperfusion
Decreased oxygen utilization	• Cyanide poisoning
Enzymatic defects	• Glycogen storage diseases (von Gierke) • Mitochondrial myopathies

©UWorld

This patient's signs and symptoms (eg, fever, leukocytosis, hypotension, tachycardia) suggest that he is in **septic shock**. Decreased bicarbonate level and increased anion gap are indicative of anion-gap metabolic acidosis secondary to an elevated lactic acid level.

Lactic acidosis may result from overproduction and/or impaired clearance of lactic acid. **End-organ hypoperfusion** in septic shock impairs tissue oxygenation and **decreases oxidative phosphorylation**, leading to a buildup of NADH and shunting of pyruvate to lactate following glycolysis. Hepatic hypoperfusion during sepsis also contributes to the accumulation of lactic acid as the liver is the primary site of lactate clearance (via conversion back into glucose).

(Choice B) Impaired hepatic gluconeogenesis occurs with several inborn errors of metabolism (eg, pyruvate carboxylase deficiency, glucose-6-

©UWorld

This patient's signs and symptoms (eg, fever, leukocytosis, hypotension, tachycardia) suggest that he is in **septic shock**. Decreased bicarbonate level and increased anion gap are indicative of anion-gap metabolic acidosis secondary to an elevated lactic acid level.

Lactic acidosis may result from overproduction and/or impaired clearance of lactic acid. **End-organ hypoperfusion** in septic shock impairs tissue oxygenation and **decreases oxidative phosphorylation**, leading to a buildup of NADH and shunting of pyruvate to lactate following glycolysis. Hepatic hypoperfusion during sepsis also contributes to the accumulation of lactic acid as the liver is the primary site of lactate clearance (via conversion back into glucose).

(Choice B) Impaired hepatic gluconeogenesis occurs with several inborn errors of metabolism (eg, pyruvate carboxylase deficiency, glucose-6-phosphatase deficiency) and can result in the buildup of lactic acid. These diseases usually present in infancy with hypoglycemia and lactic acidosis.

(Choice C) Impaired renal tubular bicarbonate reabsorption is seen in type 2 (proximal) renal tubular acidosis. Poor bicarbonate reabsorption can occur in a variety of inherited or acquired conditions, including multiple myeloma and drug toxicity (eg, acetazolamide).

(Choice D) Increased lipolysis and ketogenesis occur in patients with diabetic ketoacidosis (DKA), which also presents with anion-gap metabolic acidosis. Serum glucose is much higher in DKA (on average >350 mg/dL), and ketones can be detected in blood and urine in these patients.

(Choice E) Increased protein breakdown can occur in the setting of chronic metabolic acidosis. However, it is not a direct cause of acidosis.

Educational objective:
Lactic acidosis in septic shock results from tissue hypoxia, which impairs oxidative phosphorylation and causes shunting of pyruvate to lactate following glycolysis. Hepatic hypoperfusion also contributes to the buildup of lactic acid as the liver is the primary site of lactate clearance.

Pathology	Pulmonary & Critical Care	Metabolic acidosis
Subject	System	Topic

Copyright © UWorld. All rights reserved.

©UWorld

This patient's signs and sy ate
level and increased anion

Lactic acidosis may resu
tissue oxygenation and **de**
glycolysis. Hepatic hypop
clearance (via conversion

(Choice B) Impaired hep 6-
phosphatase deficiency) a
acidosis.

(Choice C) Impaired rena can
occur in a variety of inheri

(Choice D) Increased lipo lic
acidosis. Serum glucose

(Choice E) Increased pro

Educational objective:
Lactic acidosis in septic sh
following glycolysis. Hepa

Pathology — Subject
Pulmona — System

Exhibit Display

Anion gap metabolic acidosis	
Calculation	Anion gap = sodium – (chloride + bicarbonate) (Normal: 10-14)
Common causes Mnemonic: MUDPILES	• Methanol • Uremia • Diabetic ketoacidosis • Propylene glycol/paraldehyde • Isoniazid/iron • Lactic acidosis • Ethylene glycol (antifreeze) • Salicylates (aspirin)

Add To New Card | Existing Card

Copyright © UWorld. All rights reserved.

Item 2 of 2

The patient is treated with intravenous fluids and antibiotics, with improvement in fever, leukocytosis, and hypotension. On the third day of hospitalization, temperature is 36.7 C (98 F), blood pressure is 122/78 mm Hg, and pulse is 86/min. On examination, he is mildly lethargic and his voice is soft and breathy. Rhonchi are still heard over the lower right lung. There is left-sided facial droop and hemiparesis from his previous stroke. Chest x-ray demonstrates dense air space opacities in the superior region of the right lower lobe. Which of the following is the most likely underlying etiology of this patient's hospitalization?

- A. Decreased enteral feeding
- B. Extended immobility
- C. Impaired cellular immunity
- D. Reduced intercostal muscle strength
- E. Swallowing muscle dysfunction

Submit

Item 2 of 2

The patient is treated with intravenous fluids and antibiotics, with improvement in fever, leukocytosis, and hypotension. On the third day of hospitalization, temperature is 36.7 C (98 F), blood pressure is 122/78 mm Hg, and pulse is 86/min. On examination, he is mildly lethargic and his voice is soft and breathy. Rhonchi are still heard over the lower right lung. There is left-sided facial droop and hemiparesis from his previous stroke. Chest x-ray demonstrates dense air space opacities in the superior region of the right lower lobe. Which of the following is the most likely underlying etiology of this patient's hospitalization?

- A. Decreased enteral feeding (3%)
- B. Extended immobility (12%)
- C. Impaired cellular immunity (17%)
- D. Reduced intercostal muscle strength (8%)
- ✓ E. Swallowing muscle dysfunction (58%)

Omitted
Correct answer
E

58%
Answered correctly

02 secs
Time Spent

03/01/2020
Last Updated

Explanation

Predisposing conditions for aspiration pneumonia

Predisposing conditions for aspiration pneumonia

- Altered consciousness impairing cough reflex/glottic closure (eg, dementia, drug intoxication)
- Dysphagia due to neurologic deficits (eg, stroke, neurodegenerative disease)
- Upper gastrointestinal tract disorders (eg, GERD)
- Mechanical compromise of aspiration defenses (eg, nasogastric & endotracheal tubes)
- Protracted vomiting
- Large-volume tube feedings in recumbent position

GERD = gastroesophageal reflux disease.

©UWorld

This patient developed septic shock secondary to pneumonia (rhonchi on lung examination and radiographic lung opacities). His **history of dementia and stroke** with residual hemiparesis and evidence of vocal cord paralysis (soft, breathy voice) is highly suggestive of **aspiration pneumonia** due to inhalation of oral secretions. The superior regions of the lower lobes and posterior regions of the upper lobes are the most dependent locations in the lungs of supine individuals. Infiltrates in these locations revealed on chest x-ray are further evidence of aspiration pneumonia. Anaerobic bacteria (*Peptostreptococcus*, *Bacteroides*, *Prevotella*, *Fusobacterium*) are the dominant organisms in the oral cavity and may be isolated from cultures from patients with aspiration pneumonia.

(Choice A) Enteral feeding, specifically oral intake, increases the risk of aspiration in patients with dysphagia.

(Choices B and D) Reduced intercostal muscle strength can result in atelectasis and hypoxia. Extended immobility can produce atelectasis in the posterior lungs if the patient remains in a supine position. These conditions can also predispose to the development of pneumonia if pulmonary hygiene is inadequate. However, aspiration pneumonia is less likely in such patients as long as swallow and cough reflexes are intact.

(Choice C) Impaired cellular immunity usually results in recurrent viral and fungal infections.

(eg, nasogastric & endotracheal tubes)

- Protracted vomiting
- Large-volume tube feedings in recumbent position

GERD = gastroesophageal reflux disease.

©UWorld

This patient developed septic shock secondary to pneumonia (rhonchi on lung examination and radiographic lung opacities). His **history of dementia and stroke** with residual hemiparesis and evidence of vocal cord paralysis (soft, breathy voice) is highly suggestive of **aspiration pneumonia** due to inhalation of oral secretions. The superior regions of the lower lobes and posterior regions of the upper lobes are the most dependent locations in the lungs of supine individuals. Infiltrates in these locations revealed on chest x-ray are further evidence of aspiration pneumonia. Anaerobic bacteria (*Peptostreptococcus*, *Bacteroides*, *Prevotella*, *Fusobacterium*) are the dominant organisms in the oral cavity and may be isolated from cultures from patients with aspiration pneumonia.

(Choice A) Enteral feeding, specifically oral intake, increases the risk of aspiration in patients with dysphagia.

(Choices B and D) Reduced intercostal muscle strength can result in atelectasis and hypoxia. Extended immobility can produce atelectasis in the posterior lungs if the patient remains in a supine position. These conditions can also predispose to the development of pneumonia if pulmonary hygiene is inadequate. However, aspiration pneumonia is less likely in such patients as long as swallow and cough reflexes are intact.

(Choice C) Impaired cellular immunity usually results in recurrent viral and fungal infections.

Educational objective:
Elderly patients with dementia or hemiparesis may have dysphagia, which is a risk factor for aspiration pneumonia. Dependent lung consolidation is commonly seen in aspiration pneumonia.

Pathology	Pulmonary & Critical Care	Aspiration pneumonia
Subject	System	Topic

Copyright © UWorld. All rights reserved.

Exhibit Display

Dependent lung segments

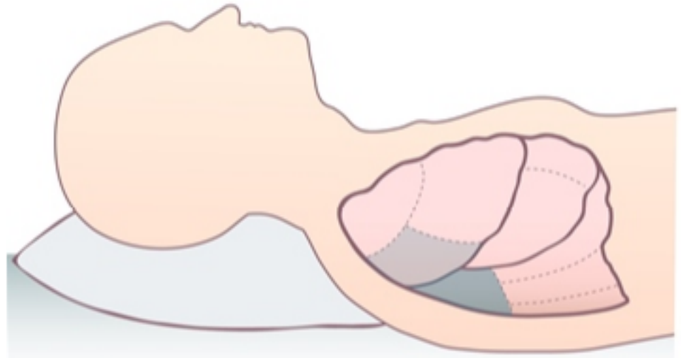

Supine
Posterior segments of upper lobes and superior segments of lower lobes most dependent

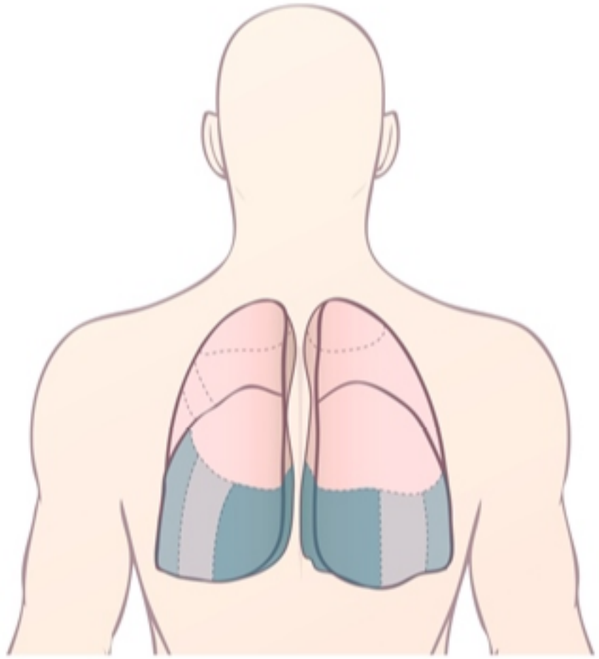

Upright
Basilar segments most dependent

©USMLEWorld, LLC

Zoom In | Zoom Out | Reset | Add To New Card | Existing Card

A 62-year-old man comes to the clinic due to a 6-month history of progressive exertional dyspnea. The patient has an occasional cough but has no palpitations, orthopnea, chest pain, or lower extremity swelling. Medical history is not significant. He works as an attorney, does not use tobacco, and drinks alcohol only on social occasions. Symptoms continue to progress, and the patient dies of respiratory failure 3 years after the initial clinic visit. Autopsy findings include heterogenous lung parenchyma with predominantly subpleural areas of dense collagen deposition and fibroblast proliferation intermixed with areas of lymphocyte infiltration and areas of normal lung tissue. Which of the following is the most likely diagnosis in this patient?

A. Alpha-1 antitrypsin deficiency
B. Asbestosis
C. Chronic bronchitis
D. Chronic hypersensitivity pneumonitis
E. Cryptogenic organizing pneumonia
F. Idiopathic pulmonary fibrosis

Submit

A 62-year-old man comes to the clinic due to a 6-month history of progressive exertional dyspnea. The patient has an occasional cough but has no palpitations, orthopnea, chest pain, or lower extremity swelling. Medical history is not significant. He works as an attorney, does not use tobacco, and drinks alcohol only on social occasions. Symptoms continue to progress, and the patient dies of respiratory failure 3 years after the initial clinic visit. Autopsy findings include heterogenous lung parenchyma with predominantly subpleural areas of dense collagen deposition and fibroblast proliferation intermixed with areas of lymphocyte infiltration and areas of normal lung tissue. Which of the following is the most likely diagnosis in this patient?

A. Alpha-1 antitrypsin deficiency (3%)
B. Asbestosis (17%)
C. Chronic bronchitis (1%)
D. Chronic hypersensitivity pneumonitis (4%)
E. Cryptogenic organizing pneumonia (6%)
✓ F. Idiopathic pulmonary fibrosis (66%)

Omitted
Correct answer
F

66%
Answered correctly

02 secs
Time Spent

02/23/2020
Last Updated

Explanation

The described histopathologic findings are consistent with **idiopathic pulmonary fibrosis** (IPF). Microscopic findings are heterogeneous and include:

Explanation

The described histopathologic findings are consistent with **idiopathic pulmonary fibrosis** (IPF). Microscopic findings are heterogeneous and include:

- Patchy areas of chronic interstitial inflammation and interstitial fibrosis intermixed with normal lung
- Early lesions consist of **fibroblastic foci** that become increasingly collagenous with time
- **Honeycomb** pattern with fibrotic walls and cystic spaces lined by bronchiolar epithelium
- Fibrosis most prominent in the **subpleural and perilobular** regions

Importantly, there should also be no other findings consistent with another disease process (eg, granulomas, microorganisms, eosinophil predominance).

The precise etiology of IPF is unclear, but risk factors include cigarette smoking, environmental pollutants, chronic aspiration, older age, and certain genetic factors (eg, telomerase mutations). Patients typically have dyspnea, nonproductive cough, finger clubbing, and inspiratory crackles. The onset is insidious, prognosis is poor, and no curative treatment exists.

(Choice A) Alpha-1 antitrypsin deficiency causes alveolar wall destruction, resulting in panacinar emphysema. Patients tend to present at a young age with dyspnea, productive cough, and wheezing. Emphysematous changes (eg, bullae) are seen predominantly at the lung bases, and histologic findings include large alveoli with thin septa.

(Choice B) Asbestosis usually occurs in patients with occupational exposures (eg, shipbuilding). Microscopy may show fibrosis and honeycombing, but asbestosis can be differentiated from IPF by the presence of asbestos bodies (brown, beaded rods coated with iron-containing material) and ferruginous bodies (inorganic particles with a similar ferrous material). Pleural plaques are also common.

(Choice C) Chronic bronchitis causes significant sputum production over a prolonged period and is often related to smoking. Histologic findings include mild lymphocytic infiltrates and mucous gland hyperplasia with mucus-filled bronchioles.

(Choice D) Chronic hypersensitivity pneumonitis is due to repeated exposure to an inciting agent (eg, birds, fungi, chemicals). Cough and dyspnea occur shortly after exposure to the antigen and may progress to respiratory failure. Histologic findings include noncaseating granulomas, peribronchiolar fibrosis, and patchy lymphocytic infiltrates.

Settings

1
2
3
4
5
6
7
8
9
10
11
12
13
14
15
16
17
18

Item 4 of 18
Question Id: 7648

Mark | Previous | Next | Full Screen | Tutorial | Lab Values | Notes | Calculator | Reverse Color | Text Zoom | Settings

Exhibit Display

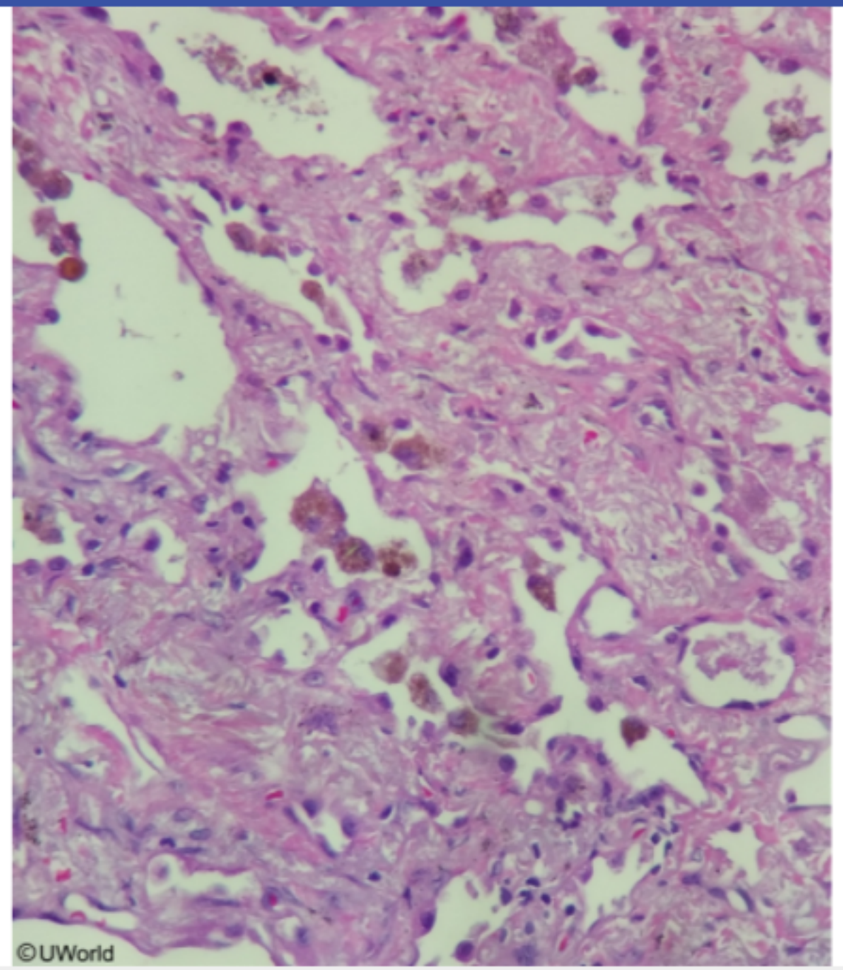

Zoom In | Zoom Out | Reset | Add To New Card | Existing Card

peribronchiolar fibrosis, and patchy lymphocytic infiltrates

Block Time Remaining: 00:00:15
TUTOR

3 | Feedback | Suspend | End Block

The precise etiology of IPF is unclear, but risk factors include cigarette smoking, environmental pollutants, chronic aspiration, older age, and certain genetic factors (eg, telomerase mutations). Patients typically have dyspnea, nonproductive cough, finger clubbing, and inspiratory crackles. The onset is insidious, prognosis is poor, and no curative treatment exists.

(Choice A) Alpha-1 antitrypsin deficiency causes alveolar wall destruction, resulting in panacinar emphysema. Patients tend to present at a young age with dyspnea, productive cough, and wheezing. Emphysematous changes (eg, bullae) are seen predominantly at the lung bases, and histologic findings include large alveoli with thin septa.

(Choice B) Asbestosis usually occurs in patients with occupational exposures (eg, shipbuilding). Microscopy may show fibrosis and honeycombing, but asbestosis can be differentiated from IPF by the presence of asbestos bodies (brown, beaded rods coated with iron-containing material) and ferruginous bodies (inorganic particles with a similar ferrous material). Pleural plaques are also common.

(Choice C) Chronic bronchitis causes significant sputum production over a prolonged period and is often related to smoking. Histologic findings include mild lymphocytic infiltrates and mucous gland hyperplasia with mucus-filled bronchioles.

(Choice D) Chronic hypersensitivity pneumonitis is due to repeated exposure to an inciting agent (eg, birds, fungi, chemicals). Cough and dyspnea occur shortly after exposure to the antigen and may progress to respiratory failure. Histologic findings include noncaseating granulomas, peribronchiolar fibrosis, and patchy lymphocytic infiltrates.

(Choice E) Cryptogenic organizing pneumonia is another fibrotic lung disease of unclear etiology that typically presents with dry cough, dyspnea, and fatigue. However, histologic findings include patchy fibrosis with fibroblastic plugs in the alveolar sacs and ducts, often extending into adjacent alveoli in a characteristic butterfly pattern.

Educational objective:
Histologic findings of idiopathic pulmonary fibrosis are most prominent in the lung periphery and include a heterogeneous mixture of chronic inflammation and patchy interstitial fibrosis, focal fibroblast proliferation, and formation of fibrotic cystic spaces in a honeycomb pattern.

References

- Idiopathic pulmonary fibrosis: evolving concepts.

Pathology Pulmonary & Critical Care Interstitial lung disease

Settings

1
2
3
4
5
6
7
8
9
10
11
12
13
14
15
16
17
18

Item 5 of 18
Question Id: 553

Mark | Previous | Next | Full Screen | Tutorial | Lab Values | Notes | Calculator | Reverse Color | Text Zoom | Settings

A 56-year-old construction worker comes to the office after receiving a letter from his employer advising him of significant exposure to asbestos during a building project 25 years ago. He is currently asymptomatic and feels well. Medical conditions include hypertension and osteoarthritis, for which he takes amlodipine daily and ibuprofen as needed. The patient quit smoking 10 years ago and does not use alcohol or illicit drugs. Physical examination is within normal limits. Chest imaging is normal. He is concerned about his risk of developing cancer. Due to his occupational exposure, this patient is at greatest risk of malignancy arising from which of the following?

A. Bronchial epithelium
B. Hematopoietic stem cells
C. Liver parenchyma
D. Nasopharyngeal epithelium
E. Pancreatic ductal cells
F. Pleura mesothelium
G. Urinary bladder epithelium

Submit

Block Time Remaining: 00:00:15
TUTOR

3 | Feedback | Suspend | End Block

A 56-year-old construction worker comes to the office after receiving a letter from his employer advising him of significant exposure to asbestos during a building project 25 years ago. He is currently asymptomatic and feels well. Medical conditions include hypertension and osteoarthritis, for which he takes amlodipine daily and ibuprofen as needed. The patient quit smoking 10 years ago and does not use alcohol or illicit drugs. Physical examination is within normal limits. Chest imaging is normal. He is concerned about his risk of developing cancer. Due to his occupational exposure, this patient is at greatest risk of malignancy arising from which of the following?

- ✓ A. Bronchial epithelium (61%)
- B. Hematopoietic stem cells (0%)
- C. Liver parenchyma (1%)
- D. Nasopharyngeal epithelium (0%)
- E. Pancreatic ductal cells (0%)
- F. Pleura mesothelium (36%)
- G. Urinary bladder epithelium (0%)

Omitted
Correct answer
A

61%
Answered correctly

02 secs
Time Spent

05/03/2020
Last Updated

Explanation

Lungs with asbestos-related disease

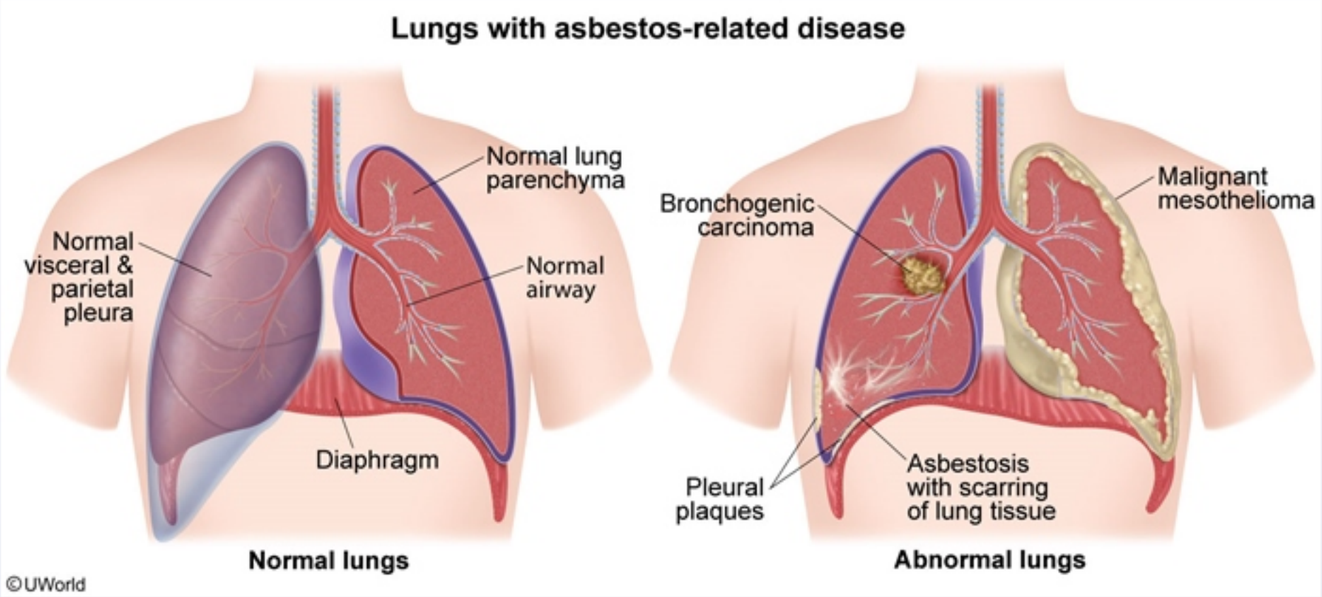

Asbestos is a fiber composed of hydrated magnesium silicates commonly used in the shipbuilding, construction, and textile industries. Inhalation of fine asbestos fibers causes epithelial cell injury, activation of macrophages, and chronic interstitial inflammation and fibrosis.

The major clinical manifestations of asbestos exposure include the following:

- **Pleural disease** includes pleural effusions and pleural plaques. Pleural plaques are a hallmark of asbestos exposure that typically affect the parietal pleura along the lower lungs and diaphragm. The plaques are composed of discrete circumscribed areas of dense collagen that frequently become calcified.
- **Asbestosis** is characterized by progressive **pulmonary fibrosis** that is most predominant in the lower lobes and by the presence of **asbestos bodies** (golden-brown beaded rods with translucent centers).
- **Bronchogenic carcinoma** is the **most common malignancy** associated with asbestos exposure. Smoking and asbestos exposure have a synergistic effect on the development of lung carcinoma, increasing the risk from 6-fold in nonsmoking patients with asbestos exposure to

parietal pleura along the lower lungs and diaphragm. The plaques are composed of discrete circumscribed areas of dense collagen that frequently become calcified.

- **Asbestosis** is characterized by progressive **pulmonary fibrosis** that is most predominant in the lower lobes and by the presence of **asbestos bodies** (golden-brown beaded rods with translucent centers).
- **Bronchogenic carcinoma** is the **most common malignancy** associated with asbestos exposure. Smoking and asbestos exposure have a synergistic effect on the development of lung carcinoma, increasing the risk from 6-fold in nonsmoking patients with asbestos exposure to 60-fold in asbestos-exposed patients who smoke regularly.
- **Malignant mesothelioma** is a rare malignancy of the pleura for which asbestos is the only known environmental risk factor. It is **less common than bronchogenic carcinoma** in asbestos-exposed patients **(Choice F)**. However, mesothelioma is more specific for heavy asbestos exposure.

(Choice B) Direct-acting alkylating agents and benzene exposure are associated with acute leukemias, which occur due to malignant proliferation of hematopoietic stem cells.

(Choice C) Aflatoxin exposure, which can occur after exposure to contaminated crops (eg, peanuts, corn), is a chemical risk factor associated with hepatocellular cancer, although viral hepatitis, cirrhosis, and alcohol abuse are more common risk factors.

(Choice D) Epstein-Barr viral infection and heavy alcohol use, particularly when combined with smoking, increase the risk of nasopharyngeal cancer.

(Choice E) Pancreatic cancer is strongly associated with tobacco use and obesity. However, this patient's asbestos exposure places him at higher risk of developing bronchogenic carcinoma.

(Choice G) Beta-naphthylamine is used in aniline dyes and the rubber industry; it is associated with increased incidence of bladder carcinoma.

Educational objective:
Patients with a long history of asbestos exposure are at risk for developing asbestosis, pleural disease, and malignancies such as bronchogenic carcinoma and mesothelioma. Bronchogenic carcinoma is the most common malignancy in this population, although mesothelioma is more specific for asbestos exposure.

synergistic effect on the development of lung carcinoma, increasing the risk from 6-fold in nonsmoking patients with asbestos exposure to 60-fold in asbestos-exposed patients who smoke regularly.

- **Malignant mesothelioma** is a rare malignancy of the pleura for which asbestos is the only known environmental risk factor. It is **less common than bronchogenic carcinoma** in asbestos-exposed patients **(Choice F)**. However, mesothelioma is more specific for heavy asbestos exposure.

(Choice B) Direct-acting alkylating agents and benzene exposure are associated with acute leukemias, which occur due to malignant proliferation of hematopoietic stem cells.

(Choice C) Aflatoxin exposure, which can occur after exposure to contaminated crops (eg, peanuts, corn), is a chemical risk factor associated with hepatocellular cancer, although viral hepatitis, cirrhosis, and alcohol abuse are more common risk factors.

(Choice D) Epstein-Barr viral infection and heavy alcohol use, particularly when combined with smoking, increase the risk of nasopharyngeal cancer.

(Choice E) Pancreatic cancer is strongly associated with tobacco use and obesity. However, this patient's asbestos exposure places him at higher risk of developing bronchogenic carcinoma.

(Choice G) Beta-naphthylamine is used in aniline dyes and the rubber industry; it is associated with increased incidence of bladder carcinoma.

Educational objective:
Patients with a long history of asbestos exposure are at risk for developing asbestosis, pleural disease, and malignancies such as bronchogenic carcinoma and mesothelioma. Bronchogenic carcinoma is the most common malignancy in this population, although mesothelioma is more specific for asbestos exposure.

Pathology	Pulmonary & Critical Care	Asbestos
Subject	System	Topic

Copyright © UWorld. All rights reserved.

A 53-year-old man comes to the office due to an 8-month history of progressive shortness of breath that peaks during strenuous activity. Several of his coworkers have experienced similar symptoms. His medical history includes hypertension and type 2 diabetes mellitus. Pulmonary examination reveals diffuse fine crackles. Chest x-ray reveals nodular densities in both lungs that are most prominent in the apical regions. Calcification of the hilar lymph nodes is also seen. Bronchoscopy with transbronchial biopsy of a calcified node is performed, and polarized microscopy shows birefringent particles surrounded by dense collagen fibers. This patient most likely has a history of exposure to which of the following substances?

A. Asbestos

B. Beryllium

C. Coal dust

D. Organic dust

E. Silica

Submit

A 53-year-old man comes to the office due to an 8-month history of progressive shortness of breath that peaks during strenuous activity. Several of his coworkers have experienced similar symptoms. His medical history includes hypertension and type 2 diabetes mellitus. Pulmonary examination reveals diffuse fine crackles. Chest x-ray reveals nodular densities in both lungs that are most prominent in the apical regions. Calcification of the hilar lymph nodes is also seen. Bronchoscopy with transbronchial biopsy of a calcified node is performed, and polarized microscopy shows birefringent particles surrounded by dense collagen fibers. This patient most likely has a history of exposure to which of the following substances?

A. Asbestos (14%)
B. Beryllium (10%)
C. Coal dust (4%)
D. Organic dust (0%)
✓ E. Silica (68%)

Omitted
Correct answer
E

68%
Answered correctly

02 secs
Time Spent

05/03/2020
Last Updated

Explanation

This middle-aged patient with dyspnea on exertion, nodular densities on x-ray, calcified hilar lymph nodes, and birefringent particles on biopsy has silicosis. **Silicosis** is a form of pneumoconiosis (ie, a type of interstitial lung disease caused by inhalation of mineral dust). Inhaled crystalline silica, typically due to **industrial exposure** (eg, mining, sand blasting), is toxic to alveolar macrophages and promotes the formation of intrapulmonary free radicals, leading to progressive lung injury and interstitial collagen deposition. Histologically, silicosis is characterized by

This middle-aged patient with dyspnea on exertion, nodular densities on x-ray, calcified hilar lymph nodes, and birefringent particles on biopsy has silicosis. **Silicosis** is a form of pneumoconiosis (ie, a type of interstitial lung disease caused by inhalation of mineral dust). Inhaled crystalline silica, typically due to **industrial exposure** (eg, mining, sand blasting), is toxic to alveolar macrophages and promotes the formation of intrapulmonary free radicals, leading to progressive lung injury and interstitial collagen deposition. Histologically, silicosis is characterized by **birefringent silicate particles** within dense, **whorled collagenous nodules** surrounded by **dust-laden macrophages**.

Silicosis is often initially asymptomatic but can present with dyspnea on exertion and productive cough, typically 10-20 years after initial exposure. Radiography varies based on disease progression; simple silicosis typically demonstrates numerous small, **rounded nodules** predominant in the **upper lobes** that may rarely coalesce to form mass-like upper lobe fibrosis (progressive massive fibrosis). Calcification of the rim of hilar nodes (**eggshell calcification**) may also be seen.

(Choice A) Asbestosis can present with dyspnea on exertion, but chest x-ray is more likely to reveal an interstitial pattern of involvement most prominent in the lower zones. Pleural plaques may also be noted. Histology shows ferruginous bodies featuring fusiform rods with a translucent asbestos center and a golden-brown iron coating.

(Choice B) Berylliosis may present with dyspnea and ill-defined nodular or irregular opacities on chest x-ray. Histology reveals noncaseating epithelioid granulomas without obvious associated particles.

(Choice C) Coal worker's pneumoconiosis can present with exertional dyspnea and nodular interstitial opacities on chest x-ray. Histology of nodal and perilymphatic lung tissue shows accumulations of black, carbon-laden macrophages (coal macules).

(Choice D) Inhalation of organic dusts can cause hypersensitivity pneumonitis. Patients have exertional dyspnea and diffuse nodular interstitial infiltrates on chest x-ray. Histology of nodal tissue may reveal noncaseating granulomas.

Educational objective:
Silicosis is characterized by dyspnea and productive cough occurring years after inhalational exposure to crystalline silica. Histologically, it is characterized by birefringent silicate particles within dense, whorled collagenous nodules surrounded by dust-laden macrophages. Radiography typically demonstrates numerous small, rounded nodules predominant in the upper lobes; calcification of the rim of hilar nodes (eggshell calcification) may also be seen.

upper lobes that may rarely coalesce to form mass-like upper lobe fibrosis (progressive massive fibrosis). Calcification of the rim of hilar nodes (**eggshell calcification**) may also be seen.

(Choice A) Asbestosis can present with dyspnea on exertion, but chest x-ray is more likely to reveal an interstitial pattern of involvement most prominent in the lower zones. Pleural plaques may also be noted. Histology shows ferruginous bodies featuring fusiform rods with a translucent asbestos center and a golden-brown iron coating.

(Choice B) Berylliosis may present with dyspnea and ill-defined nodular or irregular opacities on chest x-ray. Histology reveals noncaseating epithelioid granulomas without obvious associated particles.

(Choice C) Coal worker's pneumoconiosis can present with exertional dyspnea and nodular interstitial opacities on chest x-ray. Histology of nodal and perilymphatic lung tissue shows accumulations of black, carbon-laden macrophages (coal macules).

(Choice D) Inhalation of organic dusts can cause hypersensitivity pneumonitis. Patients have exertional dyspnea and diffuse nodular interstitial infiltrates on chest x-ray. Histology of nodal tissue may reveal noncaseating granulomas.

Educational objective:
Silicosis is characterized by dyspnea and productive cough occurring years after inhalational exposure to crystalline silica. Histologically, it is characterized by birefringent silicate particles within dense, whorled collagenous nodules surrounded by dust-laden macrophages. Radiography typically demonstrates numerous small, rounded nodules predominant in the upper lobes; calcification of the rim of hilar nodes (eggshell calcification) may also be seen.

References

- Pneumoconiosis.
- Occupational respiratory disease in mining.

Pathology	Pulmonary & Critical Care	Silicosis
Subject	System	Topic

Copyright © UWorld. All rights reserved.

Settings

1
2
3
4
5
6
7
8
9
10
11
12
13
14
15
16
17
18

Item 6 of 18
Question Id: 668

Mark | Previous | Next | Full Screen | Tutorial | Lab Values | Notes | Calculator | Reverse Color | Text Zoom | Settings

upper lobes that may rarely coalesce to form mass-like upper lobe fibrosis (progressive massive fibrosis). Calcification of the rim of hilar nodes (eggshell calcification) may also be seen.

Exhibit Display

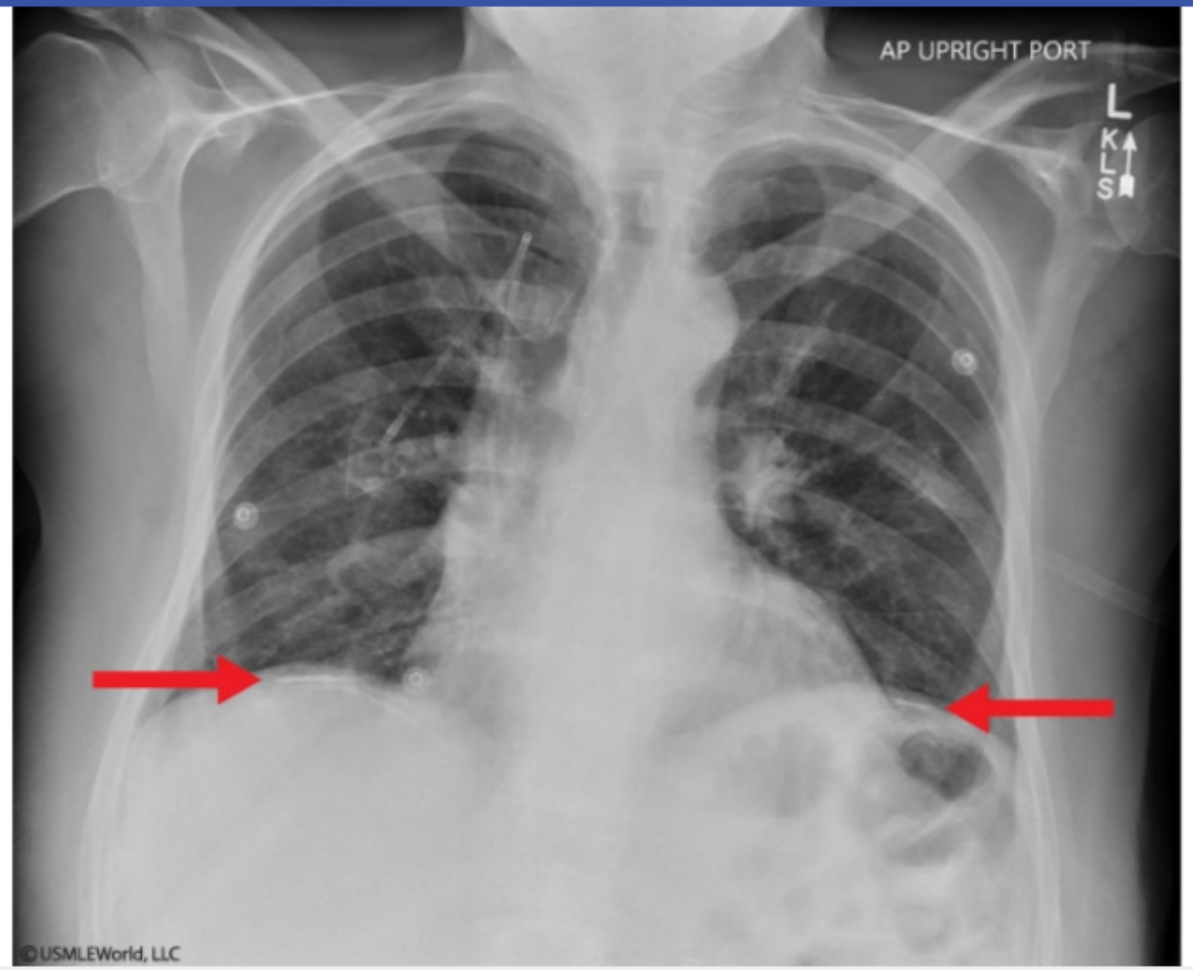

Zoom In | Zoom Out | Reset | Add To New Card | Existing Card

Block Time Remaining: 00:00:19
TUTOR

3 | Feedback | Suspend | End Block

Settings

1
2
3
4
5
6
7
8
9
10
11
12
13
14
15
16
17
18

Item 6 of 18
Question Id: 668

Mark | Previous | Next | Full Screen | Tutorial | Lab Values | Notes | Calculator | Reverse Color | Text Zoom | Settings

upper lobes that may rarely coalesce to form mass-like upper lobe fibrosis (progressive massive fibrosis). Calcification of the hilar nodes (eggshell calcification) may also be seen.

Exhibit Display

Zoom In | Zoom Out | Reset | Add To New Card | Existing Card

Block Time Remaining: 00:00:19
TUTOR

3 | Feedback | Suspend | End Block

Settings

1
2
3
4
5
6
7
8
9
10
11
12
13
14
15
16
17
18

Item 7 of 18
Question Id: 485

Mark | Previous | Next | Full Screen | Tutorial | Lab Values | Notes | Calculator | Reverse Color | Text Zoom | Settings

A 55-year-old man is hospitalized with severe abdominal pain associated with nausea and vomiting. Laboratory studies show marked elevation of serum amylase and lipase. He has a history of heavy alcohol use. During hospitalization, his condition deteriorates and he develops severe respiratory distress. There are crackles bilaterally on physical examination and infiltrates bilaterally on chest x-ray. The patient fails to improve with mechanical ventilation and 100% oxygen and dies 4 days later due to progressive respiratory failure. Which of the following autopsy findings is most likely in this patient?

A. Alveolar hyaline membranes

B. Cardiomegaly

C. Foci of anaerobic pulmonary infection

D. Intraalveolar hemorrhage

E. Lung hyperinflation

Submit

Block Time Remaining: 00:00:20
TUTOR

3 | Feedback | Suspend | End Block

A 55-year-old man is hospitalized with severe abdominal pain associated with nausea and vomiting. Laboratory studies show marked elevation of serum amylase and lipase. He has a history of heavy alcohol use. During hospitalization, his condition deteriorates and he develops severe respiratory distress. There are crackles bilaterally on physical examination and infiltrates bilaterally on chest x-ray. The patient fails to improve with mechanical ventilation and 100% oxygen and dies 4 days later due to progressive respiratory failure. Which of the following autopsy findings is most likely in this patient?

- ✓ A. Alveolar hyaline membranes (68%)
- B. Cardiomegaly (3%)
- C. Foci of anaerobic pulmonary infection (10%)
- D. Intraalveolar hemorrhage (14%)
- E. Lung hyperinflation (2%)

Omitted
Correct answer
A

68%
Answered correctly

02 secs
Time Spent

03/26/2020
Last Updated

Explanation

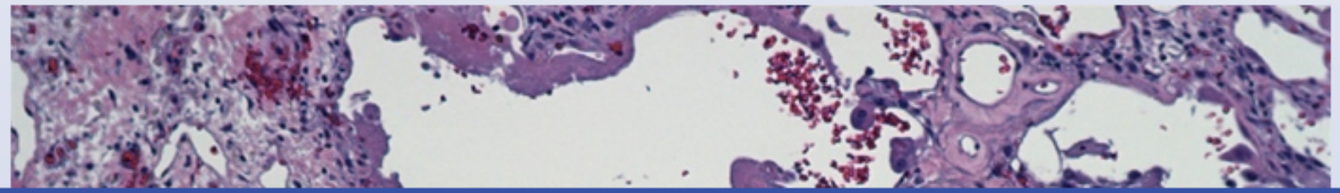

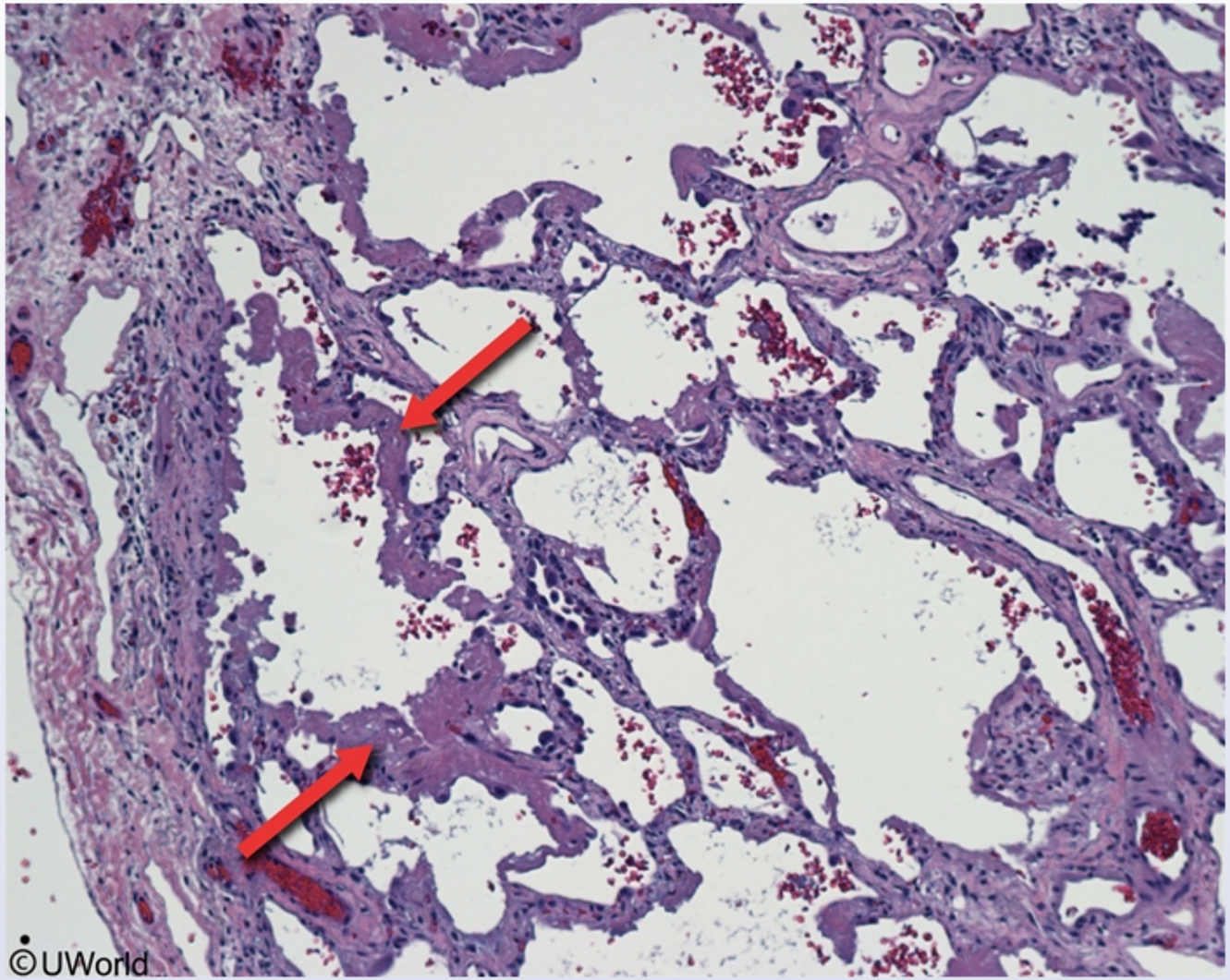

This patient with **pancreatitis** and subsequent respiratory failure likely has **acute respiratory distress syndrome** (ARDS). Pancreatitis is a major risk factor for ARDS as it results in the release of large amounts of inflammatory cytokines and pancreatic enzymes into the circulation,

This patient with **pancreatitis** and subsequent respiratory failure likely has **acute respiratory distress syndrome** (ARDS). Pancreatitis is a major risk factor for ARDS as it results in the release of large amounts of inflammatory cytokines and pancreatic enzymes into the circulation, which leads to infiltration of neutrophils into the pulmonary interstitium and alveolar spaces. Diffuse injury to the alveolar epithelium and pulmonary microvascular endothelium results in a leaky alveolocapillary membrane and significant pulmonary edema.

ARDS is typically characterized by progressive hypoxemia refractory to oxygen therapy and diffuse interstitial edema in the absence of cardiogenic causes. During the first 1-6 days, interstitial and intraalveolar edema, inflammation, and fibrin deposition cause the alveoli to become lined with waxy **hyaline membranes** (see image above). These membranes consist of fibrin exudate and inspissated protein-rich edema fluid mixed with the remnants of necrotic epithelial cells.

(Choice B) If this patient's rapid-onset dyspnea were due to cardiogenic pulmonary edema, as can occur in decompensated heart failure, or if the patient had chronic heart failure due to alcohol use, chest x-ray would likely reveal cardiomegaly. Regardless, with proper treatment, the *transudate* of cardiogenic pulmonary edema tends to resolve. This patient's progressive respiratory failure suggests a less reversible *exudative* process.

(Choice C) This patient is at risk of aspiration; however, aspiration pneumonia due to anaerobic bacteria commonly presents more indolently and is more likely to show an abscess or empyema than diffuse patchy opacities on chest x-ray.

(Choice D) Although disseminated intravascular coagulation and ARDS can result in alveolar hemorrhage, the absence of hemoptysis makes this choice less likely.

(Choices E) Lung hyperinflation may be seen in emphysema, which is a chronic, destructive enlargement of the air spaces distal to the terminal bronchiole.

Educational objective:
Pancreatitis is a major risk factor for acute respiratory distress syndrome as it results in the release of large amounts of inflammatory cytokines and pancreatic enzymes, which leads to activation of neutrophils in the alveolar tissues. During the initial phase, interstitial and intraalveolar edema, inflammation, and fibrin deposition cause the alveoli to become lined with waxy hyaline membranes.

References

waxy **hyaline membranes** (see image above). These membranes consist of fibrin exudate and inspissated protein rich edema fluid mixed with the remnants of necrotic epithelial cells.

(Choice B) If this patient's rapid-onset dyspnea were due to cardiogenic pulmonary edema, as can occur in decompensated heart failure, or if the patient had chronic heart failure due to alcohol use, chest x-ray would likely reveal cardiomegaly. Regardless, with proper treatment, the *transudate* of cardiogenic pulmonary edema tends to resolve. This patient's progressive respiratory failure suggests a less reversible *exudative* process.

(Choice C) This patient is at risk of aspiration; however, aspiration pneumonia due to anaerobic bacteria commonly presents more indolently and is more likely to show an abscess or empyema than diffuse patchy opacities on chest x-ray.

(Choice D) Although disseminated intravascular coagulation and ARDS can result in alveolar hemorrhage, the absence of hemoptysis makes this choice less likely.

(Choices E) Lung hyperinflation may be seen in emphysema, which is a chronic, destructive enlargement of the air spaces distal to the terminal bronchiole.

Educational objective:
Pancreatitis is a major risk factor for acute respiratory distress syndrome as it results in the release of large amounts of inflammatory cytokines and pancreatic enzymes, which leads to activation of neutrophils in the alveolar tissues. During the initial phase, interstitial and intraalveolar edema, inflammation, and fibrin deposition cause the alveoli to become lined with waxy hyaline membranes.

References

- The acute respiratory distress syndrome: pathogenesis and treatment.
- Acute lung injury and ARDS in acute pancreatitis: mechanisms and potential intervention.

Pathology	Pulmonary & Critical Care	ARDS
Subject	System	Topic

Copyright © UWorld. All rights reserved.

A 45-year-old woman is evaluated for progressive exertional dyspnea and fatigue. She also reports episodic pain and bluish discoloration of the fingers and toes on cold exposure that improve with rewarming. Physical examination shows skin tightening over the fingers. Cardiac examination reveals an accentuated S2 over the upper left sternal border. The abdomen is soft with mild hepatomegaly. There is bilateral lower extremity pitting edema. Pulmonary function test results are as follows:

	Observed	Predicted	% of predicted
FVC (Liters)	3.15	3.34	94
FEV_1 (Liters)	2.68	2.88	93
FEV_1/FVC ratio (%)	85		

Which of the following is the most likely cause of this patient's dyspnea?

- A. Hypoxia-induced vasoconstriction
- B. Intimal thickening of pulmonary arterioles
- C. Myocardial amyloid deposition
- D. Pericardial thickening and fibrosis
- E. Pulmonary interstitial fibrosis
- F. Right-sided valvular heart disease

Submit

A 45-year-old woman is evaluated for progressive exertional dyspnea and fatigue. She also reports episodic pain and bluish discoloration of the fingers and toes on cold exposure that improve with rewarming. Physical examination shows skin tightening over the fingers. Cardiac examination reveals an accentuated S2 over the upper left sternal border. The abdomen is soft with mild hepatomegaly. There is bilateral lower extremity pitting edema. Pulmonary function test results are as follows:

	Observed	Predicted	% of predicted
FVC (Liters)	3.15	3.34	94
FEV_1 (Liters)	2.68	2.88	93
FEV_1/FVC ratio (%)	85		

Which of the following is the most likely cause of this patient's dyspnea?

A. Hypoxia-induced vasoconstriction (5%)
✓ B. Intimal thickening of pulmonary arterioles (30%)
C. Myocardial amyloid deposition (2%)
D. Pericardial thickening and fibrosis (6%)
E. Pulmonary interstitial fibrosis (48%)
F. Right-sided valvular heart disease (6%)

Omitted
Correct answer
B

30%
Answered correctly

02 secs
Time Spent

04/04/2020
Last Updated

Pulmonary arterial hypertension

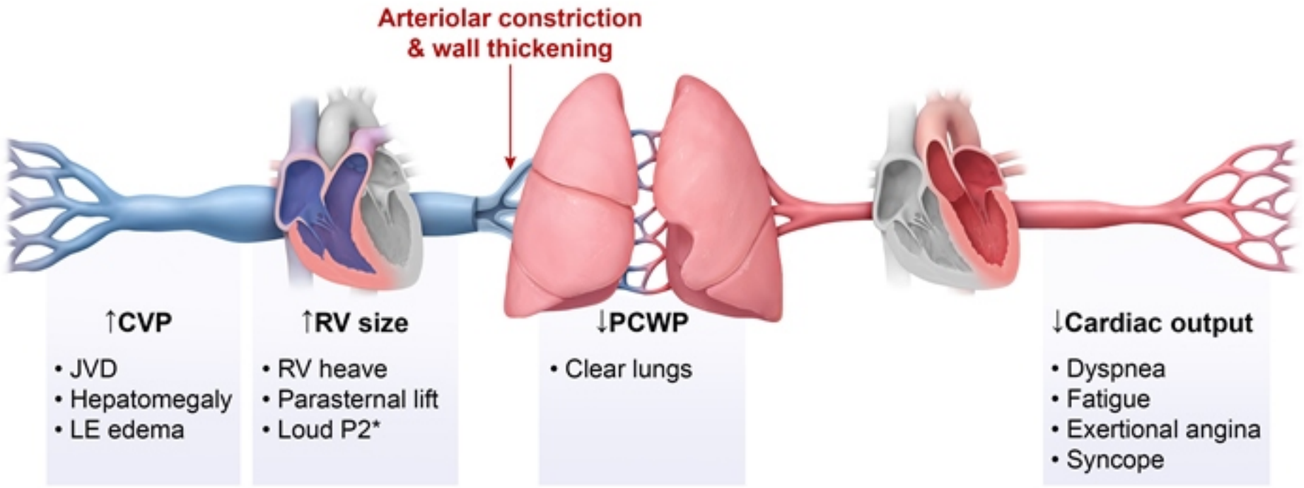

CVP = central venous pressure; **JVD** = jugular venous distension; **LE** = lower extremity; **PCWP** = pulmonary capillary wedge pressure; **RV** = right ventricular.
*Due to elevated pulmonary arterial pressure

©UWorld

This patient's skin tightening on the fingers and **Raynaud phenomenon** (cold-induced digital vasospasm) are suggestive of **CREST syndrome** (calcinosis, Raynaud phenomenon, esophageal dysmotility, sclerodactyly, telangiectasia), which is strongly associated with **systemic sclerosis**. Vascular manifestations are common in systemic sclerosis, and some patients will develop **pulmonary arterial hypertension** (PAH). In this patient, PAH is suggested by **progressive dyspnea** and a **loud pulmonic component (P2)** of S2; hepatomegaly and peripheral edema suggest consequent right-sided heart failure.

PAH results from progressive remodeling of the small and medium-sized pulmonary arteries/arterioles. In systemic sclerosis the remodeling is likely triggered by increased proliferation of T cells with secretion of a variety of cytokines (eg, TGF-beta), which stimulate fibroblasts to increase the production of collagen and extracellular matrix proteins. There is also endothelial dysfunction due to an excess of vasoconstrictive, proproliferative mediators (eg, endothelin, thromboxane A2) relative to vasodilative, antiproliferative mediators (eg, nitric oxide, prostacyclin). Consequent **vasoconstriction** and **smooth muscle proliferation** with **intimal thickening** of the vascular walls lead to increased pulmonary

This patient's skin tightening on the fingers and **Raynaud phenomenon** (cold-induced digital vasospasm) are suggestive of **CREST syndrome** (calcinosis, Raynaud phenomenon, esophageal dysmotility, sclerodactyly, telangiectasia), which is strongly associated with **systemic sclerosis**. Vascular manifestations are common in systemic sclerosis, and some patients will develop **pulmonary arterial hypertension** (PAH). In this patient, PAH is suggested by **progressive dyspnea** and a **loud pulmonic component (P2)** of S2; hepatomegaly and peripheral edema suggest consequent right-sided heart failure.

PAH results from progressive remodeling of the small and medium-sized pulmonary arteries/arterioles. In systemic sclerosis the remodeling is likely triggered by increased proliferation of T cells with secretion of a variety of cytokines (eg, TGF-beta), which stimulate fibroblasts to increase the production of collagen and extracellular matrix proteins. There is also endothelial dysfunction due to an excess of vasoconstrictive, proproliferative mediators (eg, endothelin, thromboxane A2) relative to vasodilative, antiproliferative mediators (eg, nitric oxide, prostacyclin). Consequent **vasoconstriction** and **smooth muscle proliferation** with **intimal thickening** of the vascular walls lead to increased pulmonary vascular resistance and elevated pulmonary arterial pressure. Over time, the right ventricle is unable to pump against the increased afterload, and right-sided heart failure develops.

(Choices A and E) Pulmonary interstitial fibrosis occurs in interstitial lung disease, which is a common complication of systemic sclerosis and can lead to pulmonary hypertension due to hypoxia-induced vasoconstriction. However, this patient's normal pulmonary function testing rules out significant lung disease.

(Choice C) Myocardial amyloid deposition occurs in amyloidosis and can lead to heart failure due to restrictive cardiomyopathy. Although patients can have progressive dyspnea, Raynaud phenomenon and digital skin tightening are not typical.

(Choice D) Pericardial fibrosis can occur in systemic sclerosis and typically manifests as right-sided heart failure due to impaired diastolic filling of the right ventricle. However, pulmonary arterial pressure is not typically elevated and a loud P2 is not expected.

(Choice F) Pulmonic stenosis, when severe, can lead to right-sided heart failure; however, a soft P2 would be expected.

Educational objective:
Pulmonary arterial hypertension is a common complication of systemic sclerosis, likely resulting from proliferation of T cells with release of cytokines (eg, TGF-beta) and consequent progressive thickening and occlusion of the small and medium-sized pulmonary arteries/arterioles. Patients typically have progressive dyspnea and a loud pulmonic component of S2 and may develop signs of right-sided heart failure (eg,

likely triggered by increased proliferation of T cells with secretion of a variety of cytokines (eg, TGF-beta), which stimulate fibroblasts to increase the production of collagen and extracellular matrix proteins. There is also endothelial dysfunction due to an excess of vasoconstrictive, proproliferative mediators (eg, endothelin, thromboxane A2) relative to vasodilative, antiproliferative mediators (eg, nitric oxide, prostacyclin). Consequent **vasoconstriction** and **smooth muscle proliferation** with **intimal thickening** of the vascular walls lead to increased pulmonary vascular resistance and elevated pulmonary arterial pressure. Over time, the right ventricle is unable to pump against the increased afterload, and right-sided heart failure develops.

(Choices A and E) Pulmonary interstitial fibrosis occurs in interstitial lung disease, which is a common complication of systemic sclerosis and can lead to pulmonary hypertension due to hypoxia-induced vasoconstriction. However, this patient's normal pulmonary function testing rules out significant lung disease.

(Choice C) Myocardial amyloid deposition occurs in amyloidosis and can lead to heart failure due to restrictive cardiomyopathy. Although patients can have progressive dyspnea, Raynaud phenomenon and digital skin tightening are not typical.

(Choice D) Pericardial fibrosis can occur in systemic sclerosis and typically manifests as right-sided heart failure due to impaired diastolic filling of the right ventricle. However, pulmonary arterial pressure is not typically elevated and a loud P2 is not expected.

(Choice F) Pulmonic stenosis, when severe, can lead to right-sided heart failure; however, a soft P2 would be expected.

Educational objective:
Pulmonary arterial hypertension is a common complication of systemic sclerosis, likely resulting from proliferation of T cells with release of cytokines (eg, TGF-beta) and consequent progressive thickening and occlusion of the small and medium-sized pulmonary arteries/arterioles. Patients typically have progressive dyspnea and a loud pulmonic component of S2 and may develop signs of right-sided heart failure (eg, hepatomegaly, peripheral edema).

Pathology	Pulmonary & Critical Care	Systemic sclerosis
Subject	System	Topic

Copyright © UWorld. All rights reserved.

likely triggered by increased proliferation of T cells with secretion of a variety of cytokines (eg, TGF-beta), which stimulate fibroblasts to increase the production of collagen
proproliferative mediators
Consequent **vasoconstri**
vascular resistance and e
right-sided heart failure de

(Choices A and E) Pulm
lead to pulmonary hyperte
significant lung disease.

(Choice C) Myocardial a
patients can have progres

(Choice D) Pericardial fib
the right ventricle. Howev

(Choice F) Pulmonic ste

Educational objective:
Pulmonary arterial hyperte
cytokines (eg, TGF-beta)
Patients typically have pr
hepatomegaly, peripheral

and

can

g of

Pathology
Subject

Pulmona
System

Exhibit Display

Pulmonary function test

	Normal	Obstructive lung disease	Restrictive lung disease (including obesity)
FEV1	>80% (of predicted)	Decreased	Decreased
FEV1/FVC	>70%	Decreased	Normal to increased
FVC	>80% (of predicted)	Normal to decreased	Decreased

FEV1 = forced expiratory volume in 1 second; **FVC** = forced vital capacity.

Add To New Card | Existing Card

Copyright © UWorld. All rights reserved.

The pancreas of a 22-year-old Caucasian male with recurrent pulmonary infections and finger clubbing shows extensive exocrine gland atrophy and fibrosis. The pancreatic ducts are lined with squamous epithelium with areas of keratinization. The finding of squamous metaplasia in the pancreatic ducts is most likely related to a deficiency of:

A. Riboflavin
B. Vitamin A
C. Vitamin D
D. Vitamin E
E. Vitamin K
F. Vitamin C

Submit

The pancreas of a 22-year-old Caucasian male with recurrent pulmonary infections and finger clubbing shows extensive exocrine gland atrophy and fibrosis. The pancreatic ducts are lined with squamous epithelium with areas of keratinization. The finding of squamous metaplasia in the pancreatic ducts is most likely related to a deficiency of:

- A. Riboflavin (8%)
- ✓ B. Vitamin A (56%)
- C. Vitamin D (5%)
- D. Vitamin E (18%)
- E. Vitamin K (4%)
- F. Vitamin C (7%)

Omitted
Correct answer
B

56%
Answered correctly

03 secs
Time Spent

02/03/2020
Last Updated

Explanation

Recurrent sinopulmonary infections and exocrine gland fibrotic atrophy in a young Caucasian are suggestive of cystic fibrosis (CF). In the pancreas, severe CF may cause total obstruction followed by complete fibrotic atrophy of the exocrine glands. The resulting pancreatic insufficiency can cause a deficiency of fat soluble vitamins. Avitaminosis A in particular may contribute to squamous metaplasia of the epithelial lining of pancreatic exocrine ducts, which are already injured and predisposed to squamous metaplasia by inspissated mucus. Normal levels of

Recurrent sinopulmonary infections and exocrine gland fibrotic atrophy in a young Caucasian are suggestive of cystic fibrosis (CF). In the pancreas, severe CF may cause total obstruction followed by complete fibrotic atrophy of the exocrine glands. The resulting pancreatic insufficiency can cause a deficiency of fat soluble vitamins. Avitaminosis A in particular may contribute to squamous metaplasia of the epithelial lining of pancreatic exocrine ducts, which are already injured and predisposed to squamous metaplasia by inspissated mucus. Normal levels of vitamin A and its metabolite, retinoic acid, are required to maintain orderly differentiation of specialized epithelia, including mucus-secreting columnar epithelium. When a deficiency state exists, the epithelium undergoes squamous metaplasia to a keratinizing epithelium.

(Choices A and F) Riboflavin (vitamin B_2) and vitamin C are water soluble vitamins whose intestinal absorption is not affected by fat malabsorption.

(Choice C) Vitamin D is a fat soluble vitamin. However, vitamin D deficiency would not cause epithelial squamous metaplasia. Instead, it could produce rickets in children and osteomalacia in adults.

(Choice D) Vitamin E is a fat soluble vitamin. Deficiency of this vitamin could cause infertility and decreases in some serum phospholipids.

(Choice E) Vitamin K is a fat soluble vitamin. A vitamin K deficiency could cause a coagulopathy (bleeding diathesis) secondary to inadequate vitamin K dependent clotting factors.

Educational Objective:
Recurrent sinopulmonary infections and exocrine gland fibrotic atrophy in a young Caucasian are suggestive of cystic fibrosis (CF). CF can lead to pancreatic insufficiency, fat malabsorption, and a deficiency of vitamins A, D, E and K. Vitamin A maintains orderly differentiation of specialized epithelia, including the mucus-secreting columnar epithelia of the ocular conjunctiva, respiratory and urinary tracts, and pancreatic and other exocrine ducts. Avitaminosis A can cause squamous metaplasia of such epithelia to a keratinizing epithelium.

Pathology	Pulmonary & Critical Care	Cystic fibrosis
Subject	System	Topic

Copyright © UWorld. All rights reserved.

A 67-year-old man develops severe respiratory distress and collapses. The emergency medical team finds the patient unresponsive with no pulse and he is unable to be revived despite cardiopulmonary resuscitation. A photograph of the lung as seen at autopsy is shown below.

Settings

1
2
3
4
5
6
7
8
9
10
11
12
13
14
15
16
17
18

Item 10 of 18
Question Id: 15212

Mark | Previous | Next | Full Screen | Tutorial | Lab Values | Notes | Calculator | Reverse Color | Text Zoom | Settings

Which of the following underlying histopathological changes are expected in this patient?

A. Ferruginous bodies embedded within interstitial fibrous tissue

B. Hemosiderin-laden macrophages within congested airways

C. Interalveolar septal destruction with bronchial wall inflammation

D. Multinucleated giant cells surrounding caseating granulomas

E. Necrotizing arteritis with adjacent palisading epithelioid histiocytes

F. Patchy interstitial fibrosis with the presence of fibroblastic foci

Submit

Block Time Remaining: 00:00:30
TUTOR

8 | Feedback | Suspend | End Block

Settings

1
2
3
4
5
6
7
8
9
10
11
12
13
14
15
16
17
18

Item 10 of 18
Question Id: 15212

Mark | Previous | Next | Full Screen | Tutorial | Lab Values | Notes | Calculator | Reverse Color | Text Zoom | Settings

Which of the following underlying histopathological changes are expected in this patient?

- A. Ferruginous bodies embedded within interstitial fibrous tissue (6%)
- B. Hemosiderin-laden macrophages within congested airways (17%)
- ✓ C. Interalveolar septal destruction with bronchial wall inflammation (55%)
- D. Multinucleated giant cells surrounding caseating granulomas (5%)
- E. Necrotizing arteritis with adjacent palisading epithelioid histiocytes (2%)
- F. Patchy interstitial fibrosis with the presence of fibroblastic foci (12%)

Omitted

Block Time Remaining: 00:00:32
TUTOR

8 | Feedback | Suspend | End Block

Settings

1
2
3
4
5
6
7
8
9
10
11
12
13
14
15
16
17
18

Item 10 of 18
Question Id: 15212

Mark | Previous | Next | Full Screen | Tutorial | Lab Values | Notes | Calculator | Reverse Color | Text Zoom | Settings

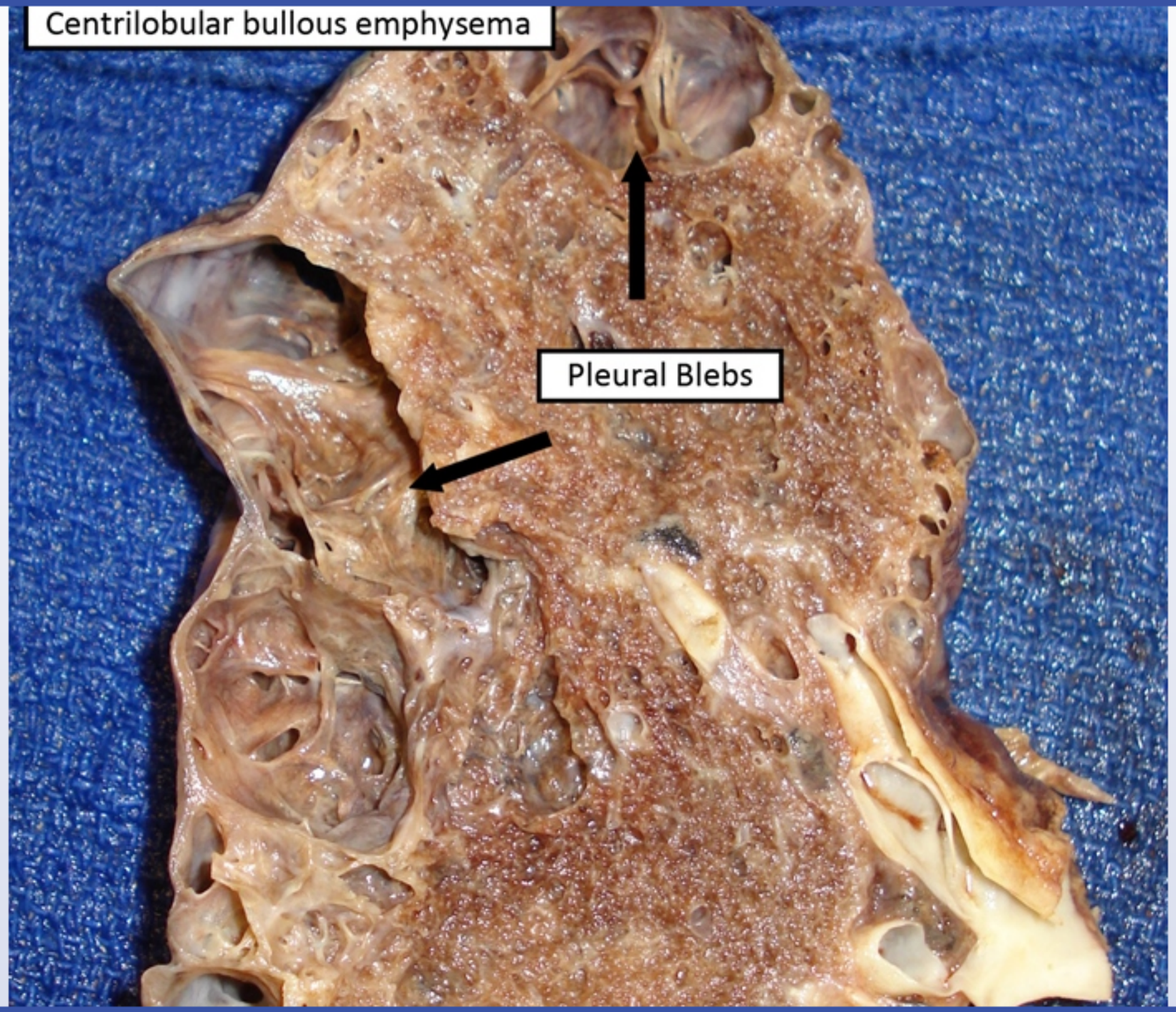

Block Time Remaining: 00:00:32
TUTOR

8 | Feedback | Suspend | End Block

The gross pathology of this patient's lung shows multiple large **subpleural blebs** consistent with severe **emphysema**. Emphysema most commonly develops due to chronic exposure to cigarette smoke via the following mechanisms:

- **Inflammation** and **leukocyte infiltration**: Alveolar macrophages release inflammatory cytokines (eg, tumor necrosis factor) and recruit neutrophils and CD8+ T lymphocytes to the alveolar tissue.
- **Protease-antiprotease imbalance**: Inflammatory cells release tissue-destructive proteases (eg, elastase) often in the setting of decreased production of antiproteases due to genetic predisposition or outright genetic mutation (eg, alpha-1 antitrypsin deficiency).
- **Oxidative stress**: Cigarette smoke and chronic inflammation increase exposure to reactive oxygen species that impart further tissue damage.

The ongoing tissue damage leads to loss of alveolar elasticity and consequent alveolar distension. In severe cases, large air spaces (>1 cm in diameter) called subpleural blebs can form, mostly in the lung apex. These subpleural blebs can sometimes rupture leading to a spontaneous pneumothorax.

(Choice A) Ferruginous bodies embedded within interstitial fibrous tissue is characteristic of pulmonary asbestosis. The ferruginous bodies represent foreign particles enclosed in iron-rich material and they typically appear as brown "barbell" shaped structures on histopathology.

(Choice B) Hemosiderin-laden macrophages (black arrow) with congested airways are consistent with pulmonary edema due to heart failure.

(Choice D) Multinucleated giant cells surrounding caseating granulomas characterize tuberculosis.

(Choice E) Necrotizing arteritis with adjacent palisading epithelioid histiocytes is consistent with granulomatosis with polyangiitis.

(Choice F) Patchy interstitial fibrosis with the presence of fibroblastic foci is consistent with idiopathic pulmonary fibrosis.

Educational objective:
Emphysema consists of alveolar destruction and enlargement that results from a combination of inflammation and leukocyte infiltration, increased protease activity, and oxidative stress, usually in response to exposure to cigarette smoke. In severe disease, large air spaces known as subpleural blebs can form in the lung apices.

Settings

1
2
3
4
5
6
7
8
9
10
11
12
13
14
15
16
17
18

Item 10 of 18
Question Id: 15212

Mark | Previous | Next | Full Screen | Tutorial | Lab Values | Notes | Calculator | Reverse Color | Text Zoom | Settings

The gross pathology of this patient's lung shows multiple large **subpleural blebs** consistent with severe **emphysema**. Emphysema most

Exhibit Display

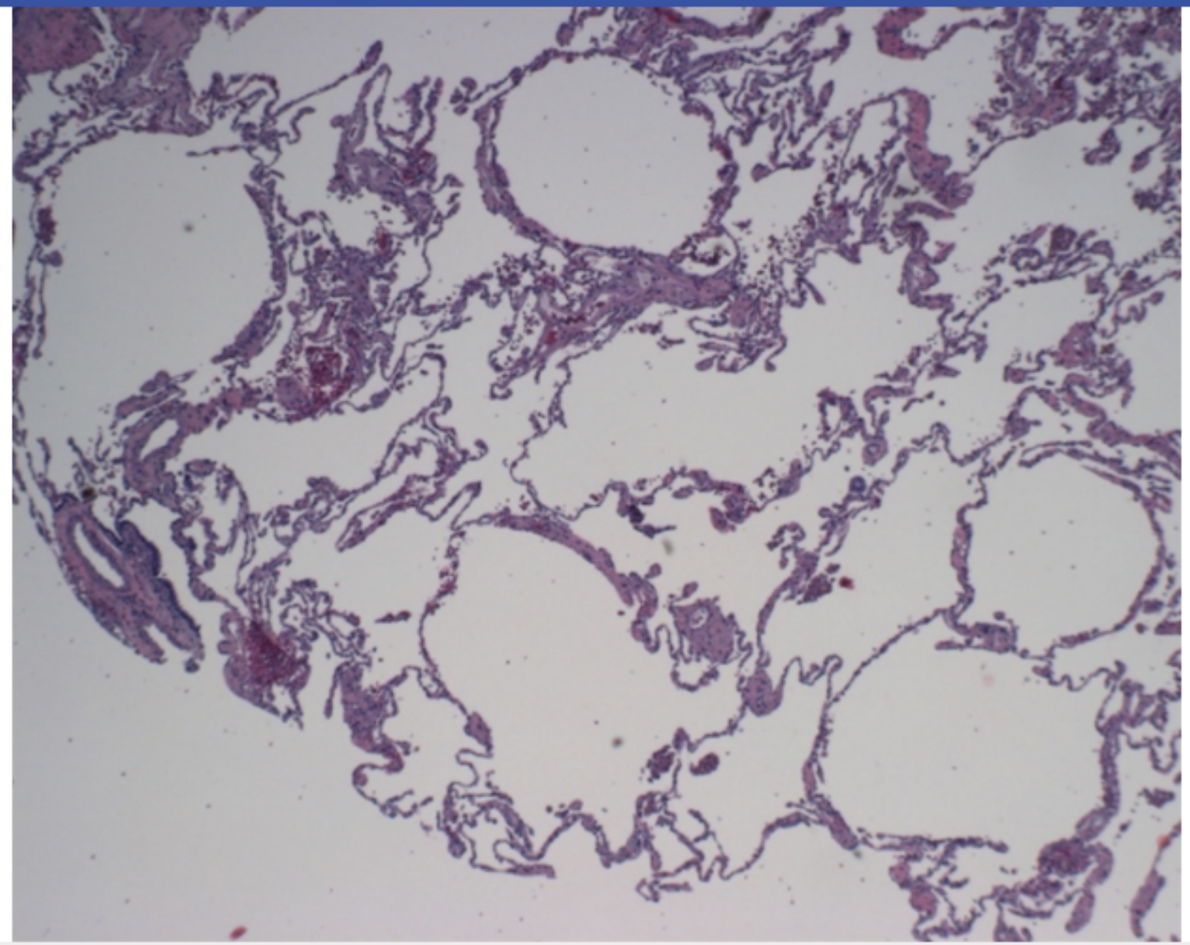

Zoom In | Zoom Out | Reset | Add To New Card | Existing Card

Block Time Remaining: 00:00:32
TUTOR

8 | Feedback | Suspend | End Block

Settings

1
2
3
4
5
6
7
8
9
10
11
12
13
14
15
16
17
18

Item 10 of 18
Question Id: 15212

Mark | Previous | Next | Full Screen | Tutorial | Lab Values | Notes | Calculator | Reverse Color | Text Zoom | Settings

The gross pathology of this patient's lung shows multiple large **subpleural blebs** consistent with severe **emphysema**. Emphysema most

Exhibit Display

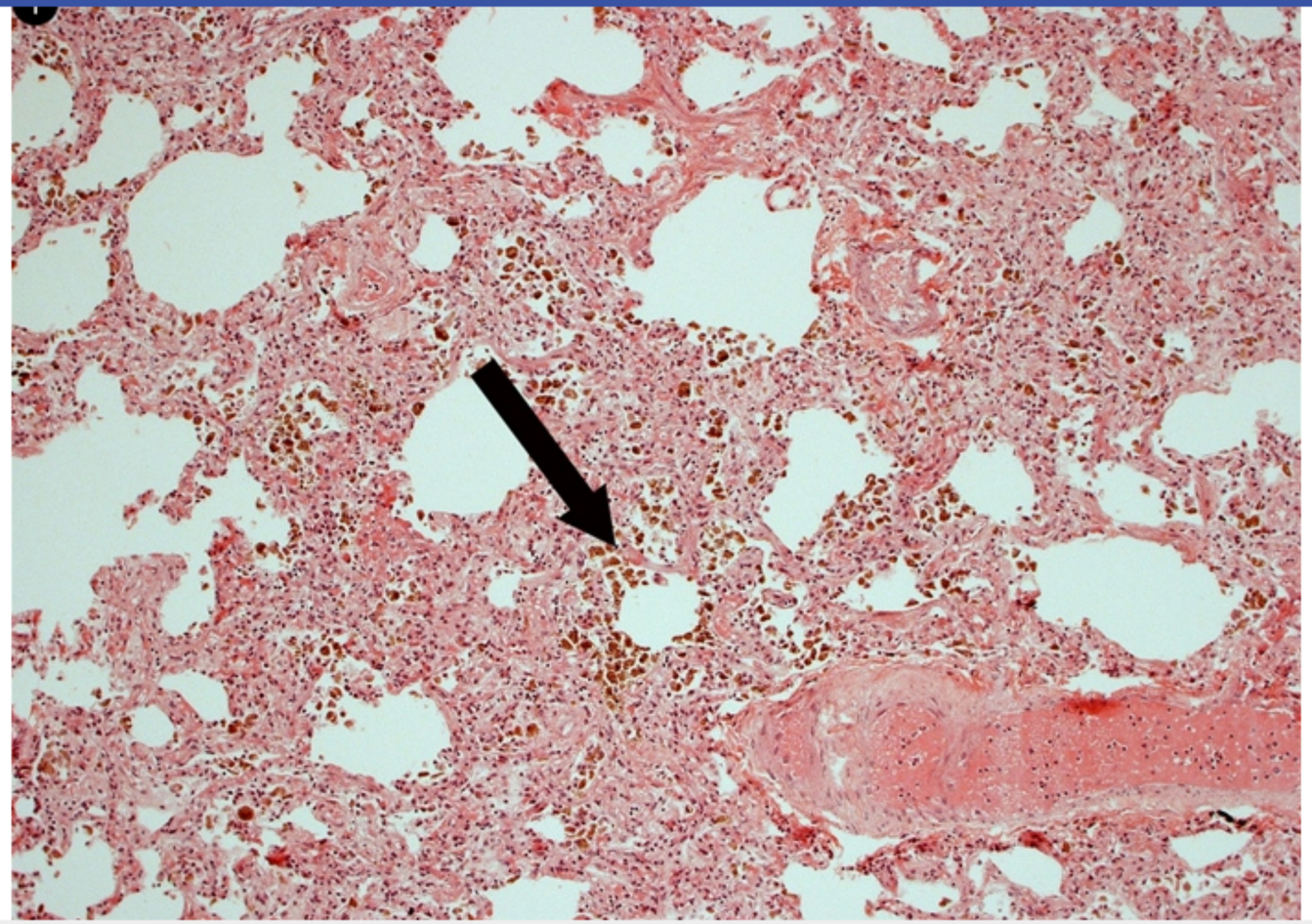

Zoom In | Zoom Out | Reset | Add To New Card | Existing Card

Block Time Remaining: 00:00:32
TUTOR

8 | Feedback | Suspend | End Block

Settings

1
2
3
4
5
6
7
8
9
10
11
12
13
14
15
16
17
18

Item 10 of 18
Question Id: 15212

Mark | Previous | Next | Full Screen | Tutorial | Lab Values | Notes | Calculator | Reverse Color | Text Zoom | Settings

The gross pathology of this patient's lung shows multiple large **subpleural blebs** consistent with severe **emphysema**. Emphysema most

Exhibit Display

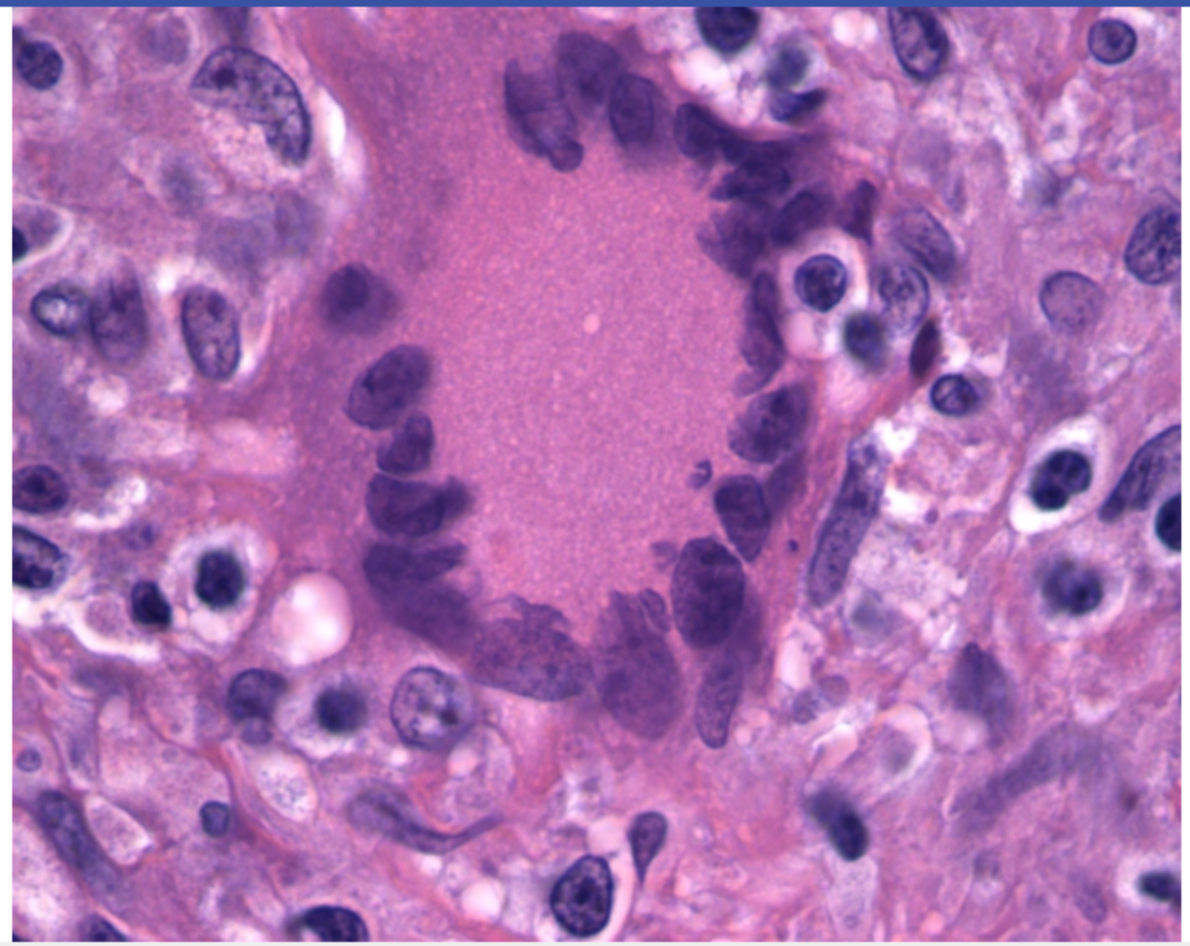

Zoom In | Zoom Out | Reset | Add To New Card | Existing Card

Block Time Remaining: 00:00:32
TUTOR

8 | Feedback | Suspend | End Block

Settings

1
2
3
4
5
6
7
8
9
10
11
12
13
14
15
16
17
18

Item 10 of 18
Question Id: 15212

Mark | Previous | Next | Full Screen | Tutorial | Lab Values | Notes | Calculator | Reverse Color | Text Zoom | Settings

The gross pathology of this patient's lung shows multiple large **subpleural blebs** consistent with severe **emphysema**. Emphysema most

Exhibit Display

Zoom In | Zoom Out | Reset | Add To New Card | Existing Card

Block Time Remaining: 00:00:32
TUTOR

8 | Feedback | Suspend | End Block

Settings

1
2
3
4
5
6
7
8
9
10
11
12
13
14
15
16
17
18

Item 10 of 18
Question Id: 15212

Mark | Previous | Next | Full Screen | Tutorial | Lab Values | Notes | Calculator | Reverse Color | Text Zoom | Settings

The gross pathology of this patient's lung shows multiple large **subpleural blebs** consistent with severe **emphysema**. Emphysema most

Exhibit Display

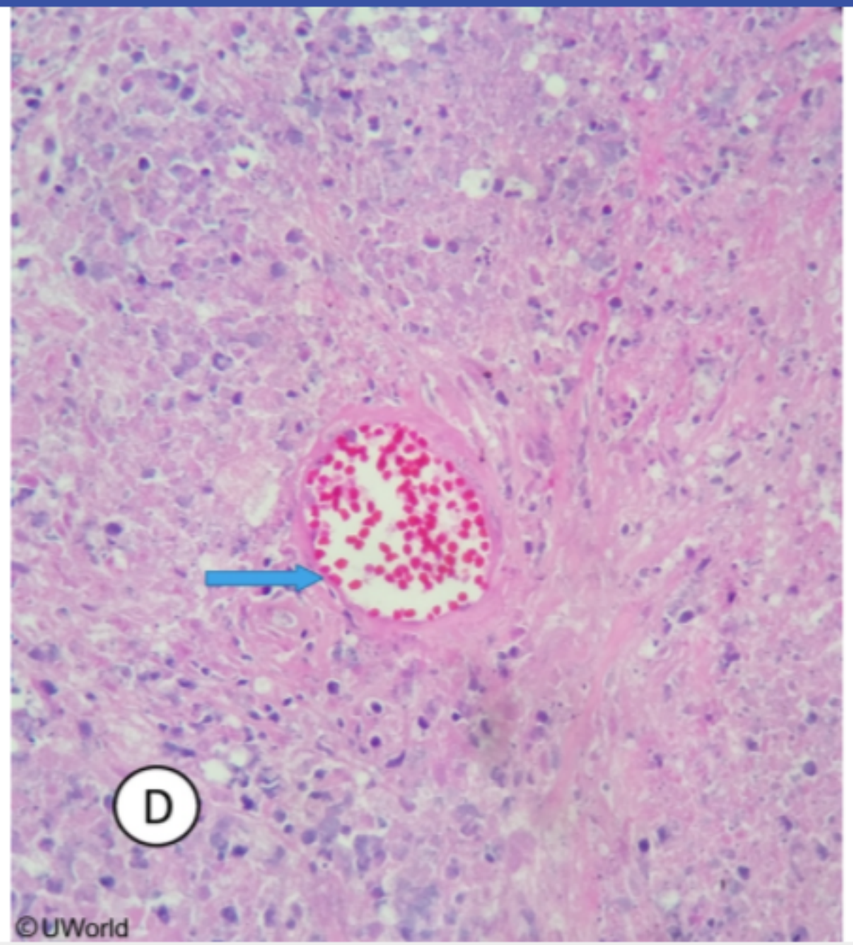

Zoom In | Zoom Out | Reset | Add To New Card | Existing Card

Block Time Remaining: 00:00:32
TUTOR

8 | Feedback | Suspend | End Block

Settings

1
2
3
4
5
6
7
8
9
10
11
12
13
14
15
16
17
18

Item 10 of 18
Question Id: 15212

Mark | Previous | Next | Full Screen | Tutorial | Lab Values | Notes | Calculator | Reverse Color | Text Zoom | Settings

- **Oxidative stress**: Cigarette smoke and chronic inflammation increase exposure to reactive oxygen species that impart further tissue

Exhibit Display

Zoom In | Zoom Out | Reset | Add To New Card | Existing Card

Block Time Remaining: 00:00:32
TUTOR

8 | Feedback | Suspend | End Block

Settings

1
2
3
4
5
6
7
8
9
10
11
12
13
14
15
16
17
18

Item 10 of 18
Question Id: 15212

Mark | Previous | Next | Full Screen | Tutorial | Lab Values | Notes | Calculator | Reverse Color | Text Zoom | Settings

- **Oxidative stress**: Cigarette smoke and chronic inflammation increase exposure to reactive oxygen species that impart further tissue

Exhibit Display

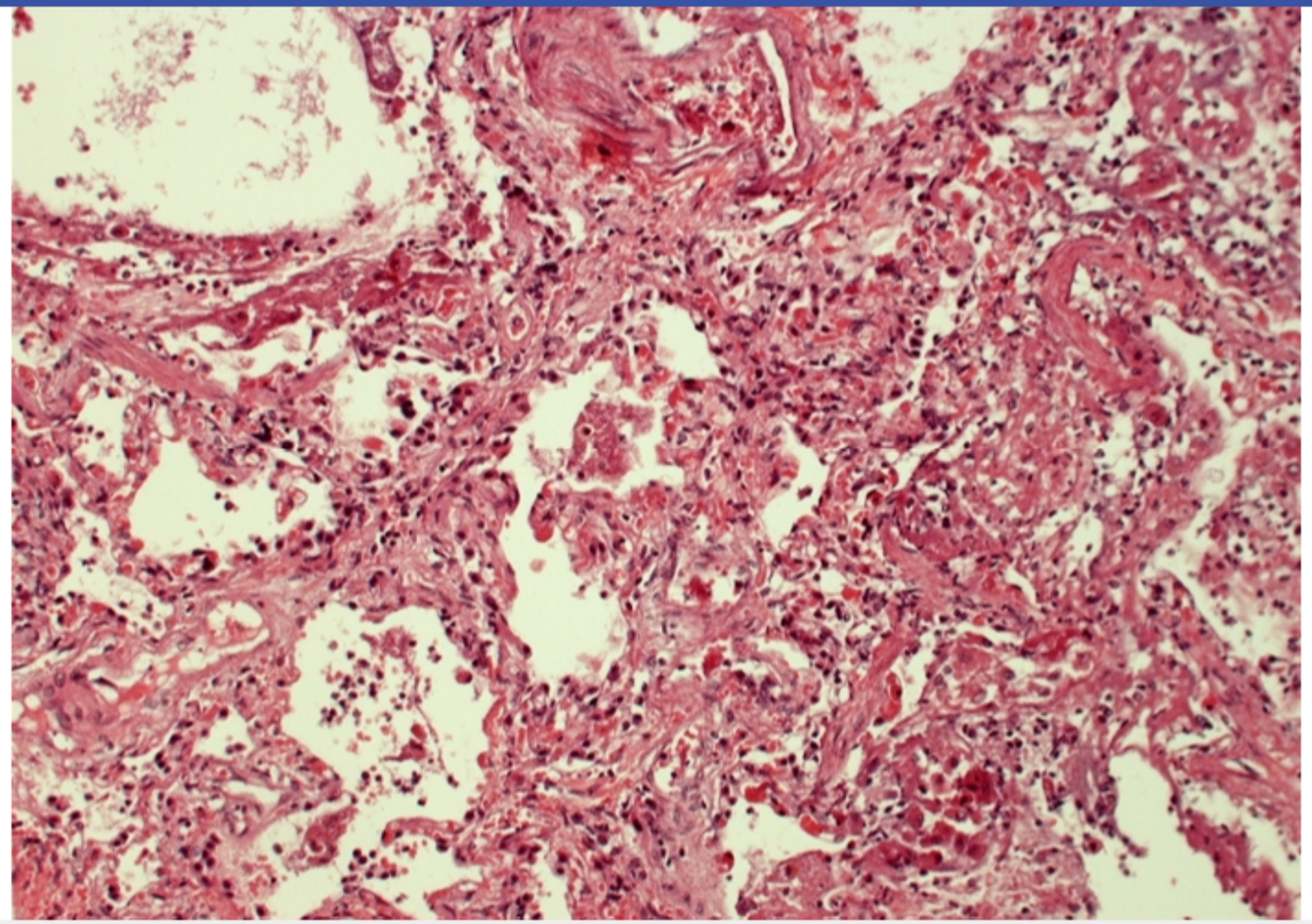

Zoom In | Zoom Out | Reset | Add To New Card | Existing Card

Block Time Remaining: 00:00:32
TUTOR

8 | Feedback | Suspend | End Block

Settings

1
2
3
4
5
6
7
8
9
10
11
12
13
14
15
16
17
18

Item 11 of 18
Question Id: 15429

Mark | Previous | Next | Full Screen | Tutorial | Lab Values | Notes | Calculator | Reverse Color | Text Zoom | Settings

A 66-year-old man comes to the office due to increasing shortness of breath over the past 3 weeks. He has had a nonproductive cough for several months, which he attributes to allergies, but also notes a 9-kg (20-lb), unintentional weight loss over this time. The patient has no prior medical conditions and takes no medications. He has a 50-pack-year smoking history. Temperature is 36.7 C (98 F), blood pressure is 120/80 mm Hg, pulse is 72/min, and respirations are 18/min. Chest x-ray is shown below.

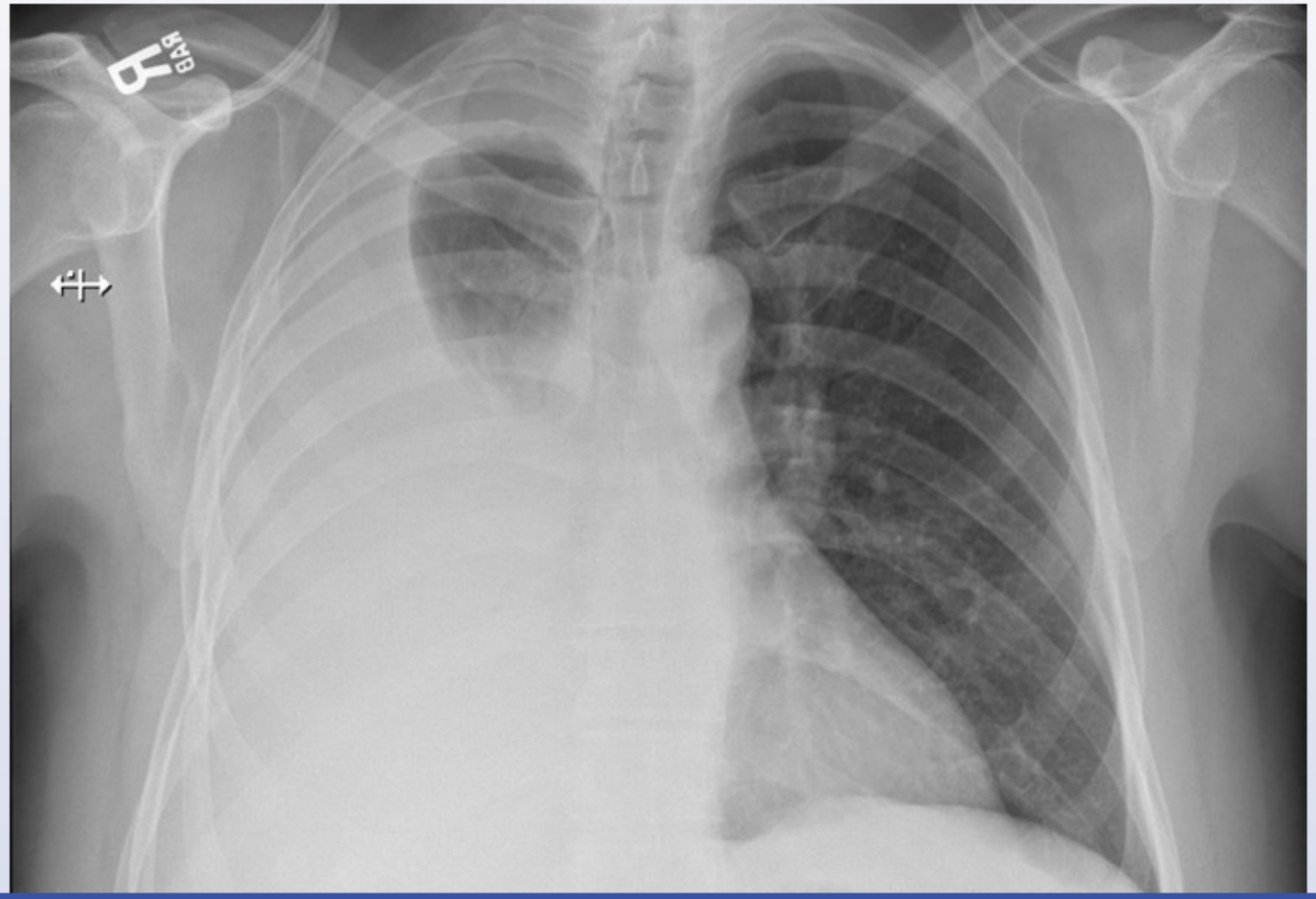

Block Time Remaining: 00:00:33
TUTOR

2 | Feedback | Suspend | End Block

Settings

Item 11 of 18
Question Id: 15429

Mark | Previous | Next | Full Screen | Tutorial | Lab Values | Notes | Calculator | Reverse Color | Text Zoom | Settings

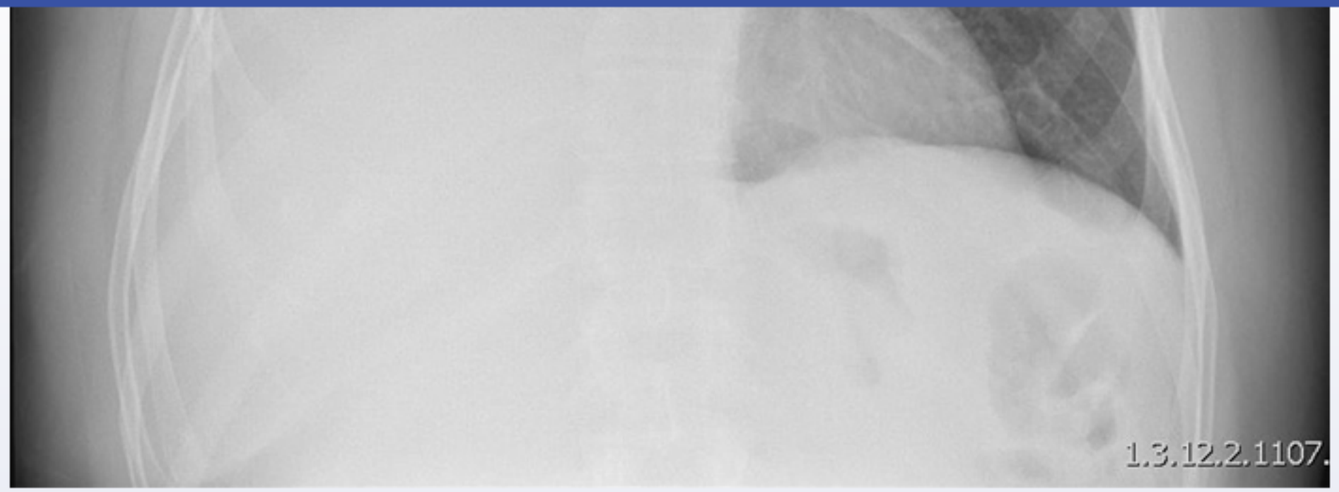

Which of the following would be the expected physical examination finding over the right lower chest?

- A. Bronchial breath sounds
- B. Decreased tactile fremitus
- C. Fine inspiratory crackles
- D. Focal, monophasic wheeze
- E. Increased resonance on percussion
- F. Rhonchi that clear with cough

Submit

Settings

1
2
3
4
5
6
7
8
9
10
11
12
13
14
15
16
17
18

Item 11 of 18
Question Id: 15429

Mark | Previous | Next | Full Screen | Tutorial | Lab Values | Notes | Calculator | Reverse Color | Text Zoom | Settings

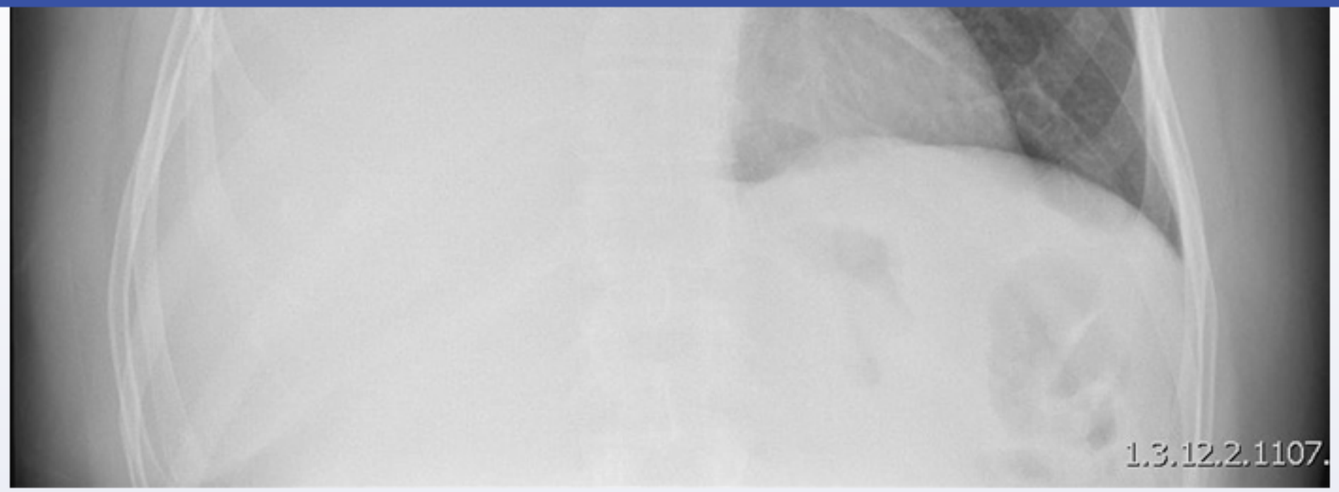

Which of the following would be the expected physical examination finding over the right lower chest?

- A. Bronchial breath sounds (12%)
- ✓ B. Decreased tactile fremitus (54%)
- C. Fine inspiratory crackles (13%)
- D. Focal, monophasic wheeze (3%)
- E. Increased resonance on percussion (14%)
- F. Rhonchi that clear with cough (1%)

Omitted
Correct answer

54%
Answered correctly

05 secs
Time Spent

05/20/2020
Last Updated

Block Time Remaining: 00:00:37
TUTOR

2 | Feedback | Suspend | End Block

Pulmonary auscultation examination findings			
Condition	**Breath sounds**	**Tactile fremitus**	**Percussion**
Normal lung	Normal	Normal	Resonance
Consolidation	Increased	Increased	Dullness
Pleural effusion	Decreased or absent	Decreased	Dullness
Pneumothorax	Decreased or absent	Decreased	Hyperresonance
Atelectasis	Decreased or absent	Decreased	Dullness

This patient's chest x-ray shows blunting of the right costophrenic angle and opacification of much of the right lung consistent with a large, right-sided **pleural effusion**. His unintentional weight loss and smoking history suggest a malignant etiology.

Pleural effusions are collections of fluid that form between the visceral pleura that lines the lung and the parietal pleura that lines the thoracic cavity. On physical examination, the fluid acts to insulate vibrations and sounds originating within the airways of the lung. Therefore, both **tactile fremitus**, the vibration created by vocalized sound (eg, saying "ninety-nine"), and **breath sounds** are **decreased** over a pleural effusion. In addition, the relatively high density of pleural fluid compared with air creates **dullness to percussion**.

(Choice A) Bronchial breath sounds describe the loud and relatively high-pitched breath sounds that are normally heard over the trachea and main bronchi; breath sounds at the periphery of the lung are typically vesicular (soft and relatively low-pitched) in nature. Bronchial breath sounds in the periphery of the lung suggest alveolar consolidation (eg, pneumonia) or fibrosis, but they should not be present with pleural effusion.

(Choice C) Inspiratory crackles are formed by alveoli and small airways popping open and may be heard with pneumonia and atelectasis. The descriptor "fine" is often used to describe soft, high-pitch inspiratory crackles associated with pulmonary fibrosis.

(Choice D) A focal, monophasic wheeze may suggest partial obstruction of a large airway (eg, due to a foreign body or tumor).

cavity. On physical examination, the fluid acts to insulate vibrations and sounds originating within the airways of the lung. Therefore, both **tactile fremitus**, the vibration created by vocalized sound (eg, saying "ninety-nine"), and **breath sounds** are **decreased** over a pleural effusion. In addition, the relatively high density of pleural fluid compared with air creates **dullness to percussion**.

(Choice A) Bronchial breath sounds describe the loud and relatively high-pitched breath sounds that are normally heard over the trachea and main bronchi; breath sounds at the periphery of the lung are typically vesicular (soft and relatively low-pitched) in nature. Bronchial breath sounds in the periphery of the lung suggest alveolar consolidation (eg, pneumonia) or fibrosis, but they should not be present with pleural effusion.

(Choice C) Inspiratory crackles are formed by alveoli and small airways popping open and may be heard with pneumonia and atelectasis. The descriptor "fine" is often used to describe soft, high-pitch inspiratory crackles associated with pulmonary fibrosis.

(Choice D) A focal, monophasic wheeze may suggest partial obstruction of a large airway (eg, due to a foreign body or tumor).

(Choice E) Percussion notes exist on a spectrum. Normal lung, which represents a composite of parenchymal tissue and air, generates sound that is considered resonant to percussion. The relatively lower density of air alone (ie, pneumothorax) causes hyperresonance to percussion.

(Choice F) Rhonchi are coarse rattling or wheezing sounds that are caused by mucus secretions in the airways and may be heard in patients with chronic obstructive pulmonary disease or bronchiectasis. Rhonchi will often clear with coughing. They are not an expected finding with pleural effusion.

Educational objective:
A pleural effusion is a collection of fluid between the visceral pleura that lines the lungs and the parietal pleura that lines the thoracic cavity. The fluid acts to insulate vibrations and sounds that originate in the airways of the lung; therefore, tactile fremitus and breath sounds are decreased over a pleural effusion. Dullness to percussion is also present.

Pathology	Pulmonary & Critical Care	Pleural effusion
Subject	System	Topic

Copyright © UWorld. All rights reserved.

Settings

1
2
3
4
5
6
7
8
9
10
11
12
13
14
15
16
17
18

Item 12 of 18
Question Id: 486

Mark | Previous | Next | Full Screen | Tutorial | Lab Values | Notes | Calculator | Reverse Color | Text Zoom | Settings

A 32-year-old man is hospitalized due to nausea, vomiting, and severe abdominal pain. He has a history of heavy alcohol use and was admitted to the hospital for acute pancreatitis a year ago. He has continued to drink alcohol since his last hospitalization and had a party last weekend, during which he consumed an entire 750-mL bottle of liquor. Temperature is 38.3 C (100.9 F), blood pressure is 110/80 mm Hg, pulse is 104/min, and respirations are 20/min. Abdominal examination is notable for marked tenderness in the epigastric region. Serum lipase is 2,392 U/L. The patient is admitted and started on intravenous fluids, analgesics, and antiemetics with subsequent improvement in his symptoms. His vital signs remain stable with adequate urine output. However, on the second day of hospitalization, the patient develops progressive shortness of breath and hypoxemia. Chest x-ray reveals new bilateral opacities. Which of the following parameters is most likely to be normal in this patient?

A. Capillary permeability

B. Lung compliance

C. Pulmonary capillary wedge pressure

D. Ventilation/perfusion matching

E. Work of breathing

Submit

Block Time Remaining: 00:00:38
TUTOR

3 | Feedback | Suspend | End Block

A 32-year-old man is hospitalized due to nausea, vomiting, and severe abdominal pain. He has a history of heavy alcohol use and was admitted to the hospital for acute pancreatitis a year ago. He has continued to drink alcohol since his last hospitalization and had a party last weekend, during which he consumed an entire 750-mL bottle of liquor. Temperature is 38.3 C (100.9 F), blood pressure is 110/80 mm Hg, pulse is 104/min, and respirations are 20/min. Abdominal examination is notable for marked tenderness in the epigastric region. Serum lipase is 2,392 U/L. The patient is admitted and started on intravenous fluids, analgesics, and antiemetics with subsequent improvement in his symptoms. His vital signs remain stable with adequate urine output. However, on the second day of hospitalization, the patient develops progressive shortness of breath and hypoxemia. Chest x-ray reveals new bilateral opacities. Which of the following parameters is most likely to be normal in this patient?

- A. Capillary permeability (10%)
- B. Lung compliance (24%)
- ✓ C. Pulmonary capillary wedge pressure (53%)
- D. Ventilation/perfusion matching (8%)
- E. Work of breathing (3%)

Omitted
Correct answer
C

53%
Answered correctly

02 secs
Time Spent

04/10/2020
Last Updated

Explanation

Acute respiratory distress syndrome

Acute respiratory distress syndrome	
Risk factors	• Sepsis, pneumonia • Trauma • Pancreatitis
Pathophysiology	• Cytokine release, endothelial activation • Neutrophil recruitment & degranulation in lung • ↑ Capillary permeability, alveolar fluid accumulation • Formation of hyaline membrane
Clinical features	• Hypoxia • Bilateral pulmonary infiltrates • Normal pulmonary capillary wedge pressure (6-12 mm Hg)

This patient with **pancreatitis** (abdominal pain, elevated lipase, recent heavy alcohol intake) has developed hypoxic respiratory failure with bilateral pulmonary infiltrates. In a young patient without a history of cardiac disease, this is highly suggestive of **acute respiratory distress syndrome** (ARDS). Direct (eg, irritant chemicals, trauma, gastric aspiration) or indirect (eg, pancreatitis, sepsis) pulmonary insults cause excessive cytokine release, leading to endothelial activation, neutrophilic migration to the lungs, and degranulation with release of toxic mediators. This process worsens the pulmonary alveolar and endothelial injury, leading to **increased pulmonary capillary permeability**, leakage of fluid into the alveoli, and pulmonary edema **(Choice A)**.

ARDS-associated interstitial edema and hyaline membrane formation along with fluid-filled alveoli collapse and atelectasis result in **decreased lung compliance** and increased work of breathing **(Choices B and E)**. The fluid-filled, collapsed alveoli are unable to deliver oxygen despite continuing to receive adequate blood flow, resulting in **ventilation/perfusion mismatch** (ie, physiologic shunting) and hypoxia **(Choice D)**.

Noncardiogenic pulmonary edema (eg, ARDS, high-altitude pulmonary edema) can be distinguished from cardiogenic pulmonary edema (eg, decompensated left ventricular failure, volume overload) by a **normal pulmonary capillary wedge pressure** (6-12 mm Hg). Other distinguishing features include the clinical history (pneumonia/sepsis or pancreatitis suggests ARDS) and physical exam (peripheral edema and jugular venous

Clinical features	• Bilateral pulmonary infiltrates • Normal pulmonary capillary wedge pressure (6-12 mm Hg)

This patient with **pancreatitis** (abdominal pain, elevated lipase, recent heavy alcohol intake) has developed hypoxic respiratory failure with bilateral pulmonary infiltrates. In a young patient without a history of cardiac disease, this is highly suggestive of **acute respiratory distress syndrome** (ARDS). Direct (eg, irritant chemicals, trauma, gastric aspiration) or indirect (eg, pancreatitis, sepsis) pulmonary insults cause excessive cytokine release, leading to endothelial activation, neutrophilic migration to the lungs, and degranulation with release of toxic mediators. This process worsens the pulmonary alveolar and endothelial injury, leading to **increased pulmonary capillary permeability**, leakage of fluid into the alveoli, and pulmonary edema **(Choice A)**.

ARDS-associated interstitial edema and hyaline membrane formation along with fluid-filled alveoli collapse and atelectasis result in **decreased lung compliance** and increased work of breathing **(Choices B and E)**. The fluid-filled, collapsed alveoli are unable to deliver oxygen despite continuing to receive adequate blood flow, resulting in **ventilation/perfusion mismatch** (ie, physiologic shunting) and hypoxia **(Choice D)**.

Noncardiogenic pulmonary edema (eg, ARDS, high-altitude pulmonary edema) can be distinguished from cardiogenic pulmonary edema (eg, decompensated left ventricular failure, volume overload) by a **normal pulmonary capillary wedge pressure** (6-12 mm Hg). Other distinguishing features include the clinical history (pneumonia/sepsis or pancreatitis suggests ARDS) and physical exam (peripheral edema and jugular venous distension suggest a cardiogenic source).

Educational objective:
Acute respiratory distress syndrome is characterized by hypoxia and bilateral pulmonary infiltrates and is associated with pneumonia, sepsis, trauma, and pancreatitis. The associated pulmonary edema is noncardiogenic in nature, so the pulmonary capillary wedge pressure will be within the normal range (6-12 mm Hg).

Pathology	Pulmonary & Critical Care	ARDS
Subject	System	Topic

Copyright © UWorld. All rights reserved.

Settings

1
2
3
4
5
6
7
8
9
10
11
12
13
14
15
16
17
18

Item 12 of 18
Question Id: 486

Mark | Previous | Next | Full Screen | Tutorial | Lab Values | Notes | Calculator | Reverse Color | Text Zoom | Settings

Clinical features
- Bilateral pulmonary infiltrates

Exhibit Display

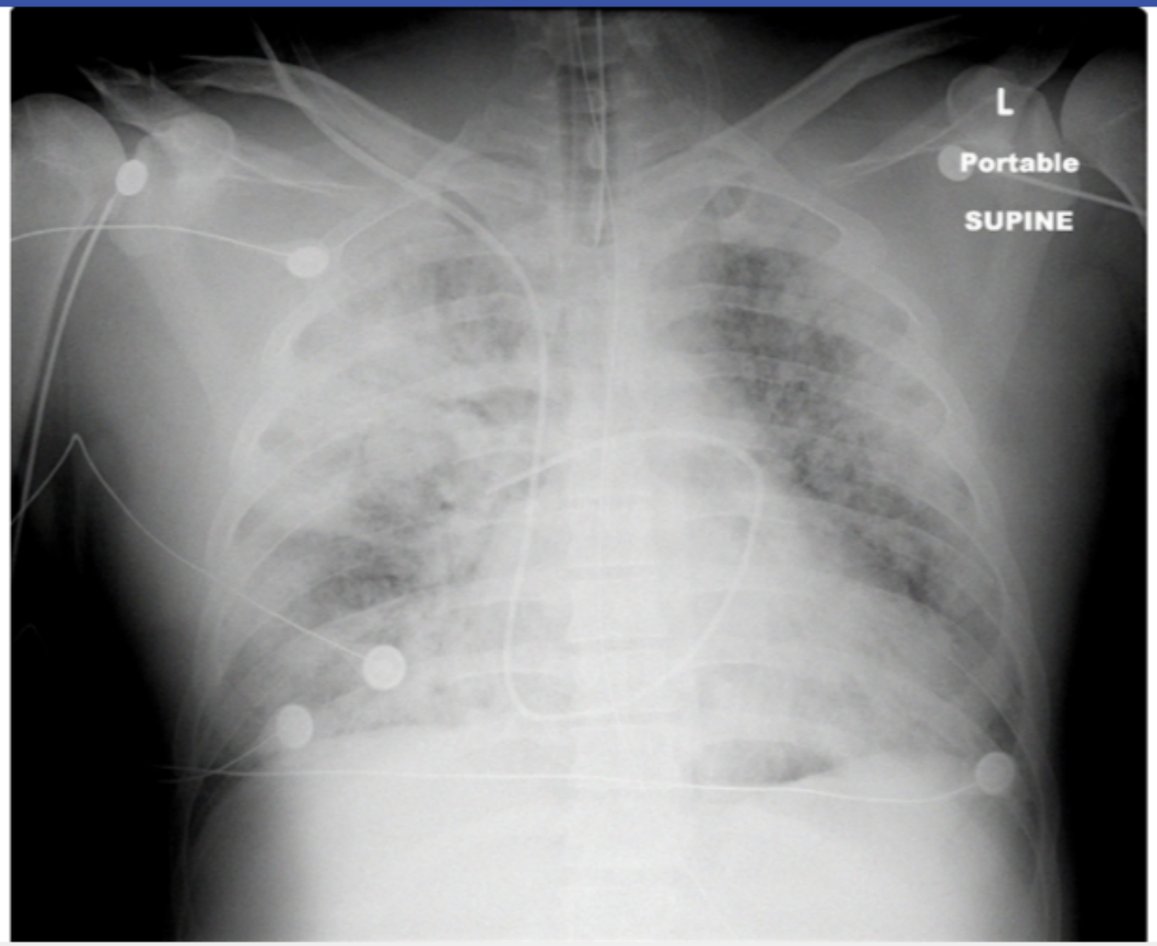

Zoom In | Zoom Out | Reset | Add To New Card | Existing Card

Block Time Remaining: 00:00:39
TUTOR

3 | Feedback | Suspend | End Block

A 64-year-old man is evaluated for worsening cough and shortness of breath. The patient has a history of hypertension and type 2 diabetes mellitus. He smokes a pack of cigarettes daily and drinks alcohol occasionally. Temperature is 38 C (100.4 F), blood pressure is 140/82 mm Hg, and pulse is 92/min. Lung auscultation reveals abnormal breath sounds. Chest x-ray is shown below.

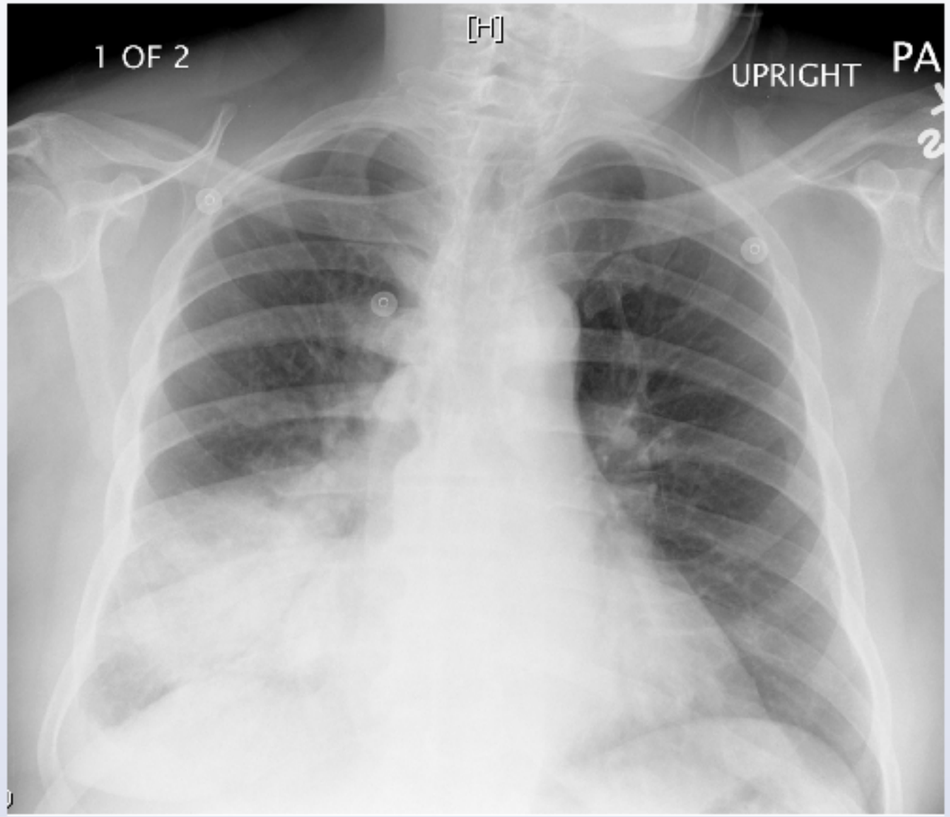

Which of the following is the most likely cause of the observed pulmonary findings in this patient?

A. Elevated pulmonary capillary hydrostatic pressure

Settings

1
2
3
4
5
6
7
8
9
10
11
12
13
14
15
16
17
18

Item 13 of 18
Question Id: 531

Mark | Previous | Next | Full Screen | Tutorial | Lab Values | Notes | Calculator | Reverse Color | Text Zoom | Settings

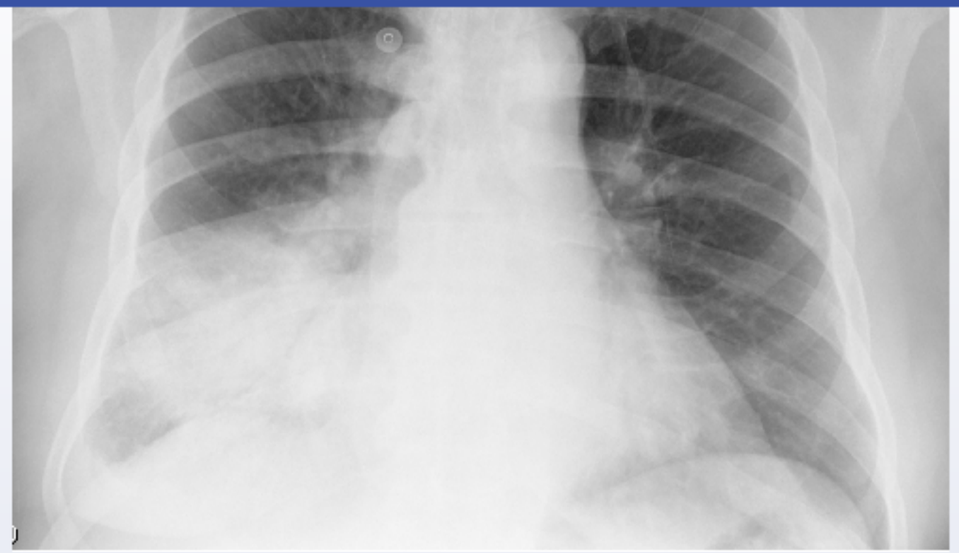

Which of the following is the most likely cause of the observed pulmonary findings in this patient?

A. Elevated pulmonary capillary hydrostatic pressure

B. Exaggerated reactivity and inflammation of the airways

C. Excessive fibroblast proliferation and extracellular matrix deposition

D. Leakage of protein-rich fluid in the alveolar airspaces

E. Mucous gland hyperplasia and inflammation in the large airways

Submit

Block Time Remaining: 00:00:43
TUTOR

5 | Feedback | Suspend | End Block

Settings

1
2
3
4
5
6
7
8
9
10
11
12
13
14
15
16
17
18

Item 13 of 18
Question Id: 531

Mark | Previous | Next | Full Screen | Tutorial | Lab Values | Notes | Calculator | Reverse Color | Text Zoom | Settings

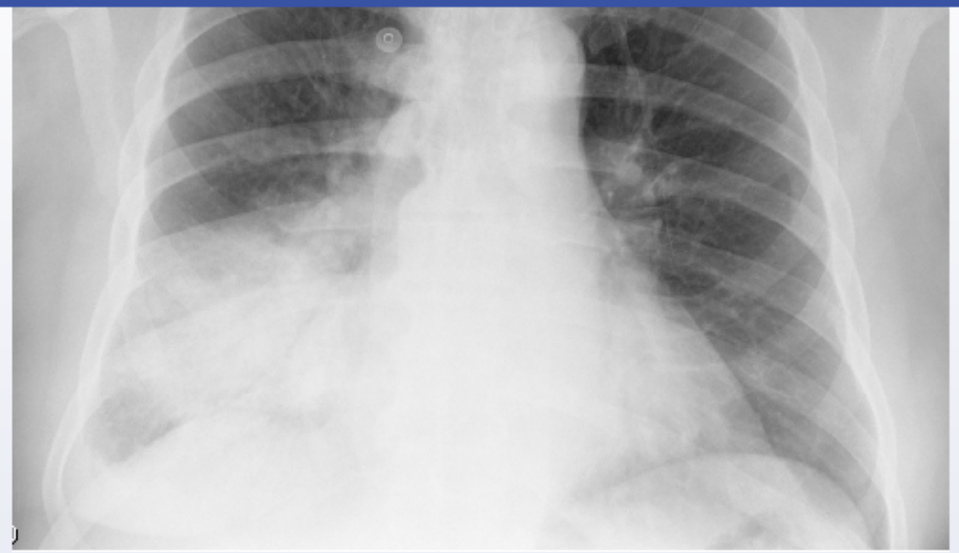

Which of the following is the most likely cause of the observed pulmonary findings in this patient?

A. Elevated pulmonary capillary hydrostatic pressure (18%)

B. Exaggerated reactivity and inflammation of the airways (9%)

C. Excessive fibroblast proliferation and extracellular matrix deposition (8%)

✓ D. Leakage of protein-rich fluid in the alveolar airspaces (45%)

E. Mucous gland hyperplasia and inflammation in the large airways (18%)

Omitted
Correct answer

45%
Answered correctly

05 secs
Time Spent

06/01/2020
Last Updated

Block Time Remaining: 00:00:44
TUTOR

5 | Feedback | Suspend | End Block

Settings

1
2
3
4
5
6
7
8
9
10
11
12
13
14
15
16
17
18

Item 13 of 18
Question Id: 531

Mark | Previous | Next | Full Screen | Tutorial | Lab Values | Notes | Calculator | Reverse Color | Text Zoom | Settings

Morphologic stages of lobar pneumonia

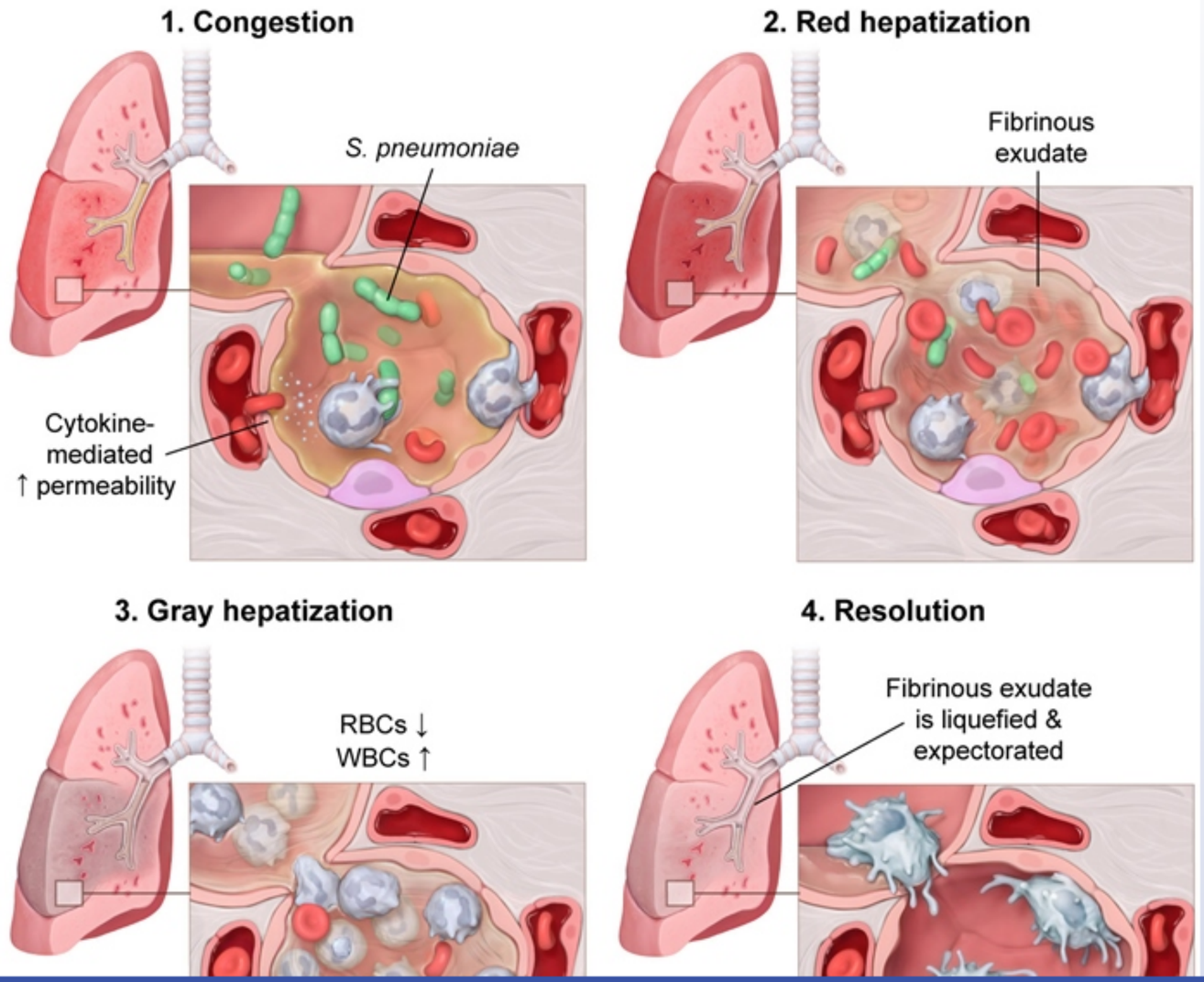

Block Time Remaining: 00:00:44
TUTOR

5 | Feedback | Suspend | End Block

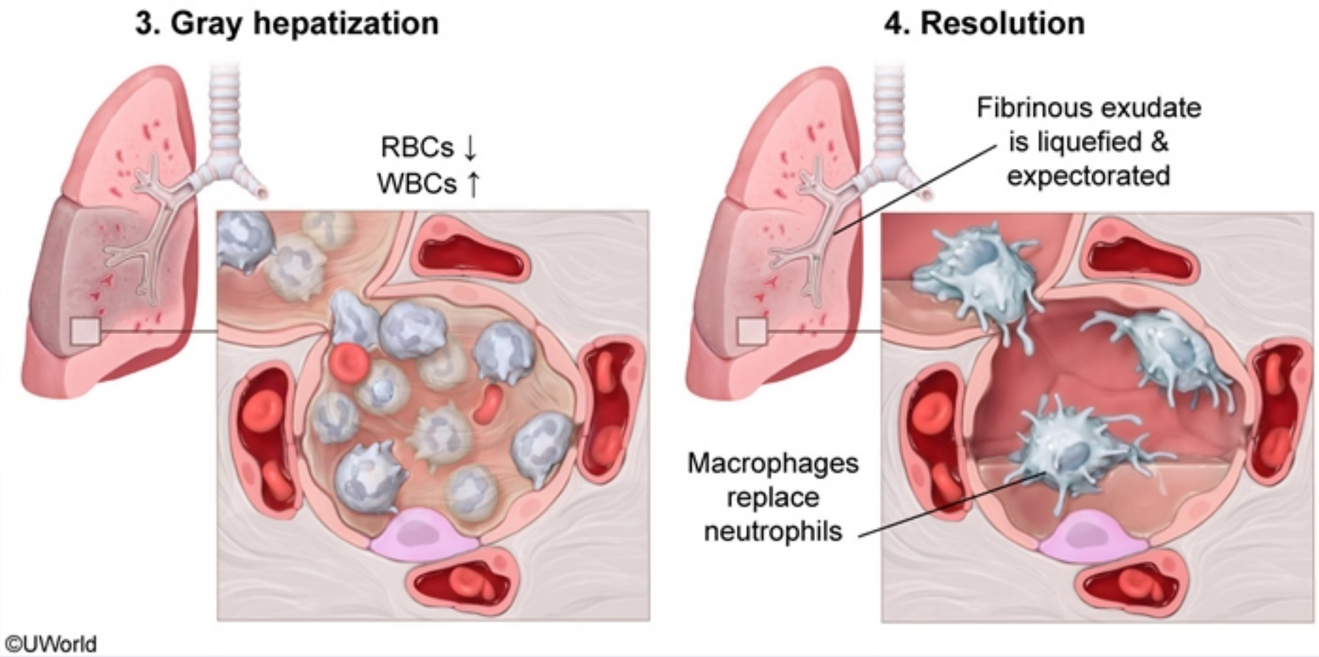

This patient has cough, shortness of breath, fever, and a right lower lobe infiltrate on chest x-ray, indicating **lobar pneumonia** likely due to a community-acquired pathogen (eg, *Streptococcus pneumoniae*). Lobar pneumonia is characterized by a step-wise inflammatory response, as follows:

1. **Congestion** (day 0-2) – Neutrophils respond to bacterial components (eg, peptidoglycan) by releasing cytokines that **increase the permeability** of the pulmonary capillary endothelium, which allows circulating immune cells to more easily migrate to the area. Increased capillary permeability also leads to the accumulation of erythrocytes and **abundant proteinaceous fluid** in the alveolar space, resulting in the affected lobe becoming heavy and red.

2. **Red hepatization** (day 2-4) – The proteinaceous fluid transforms into fibrin strands, resulting in a confluent exudate of fibrin, neutrophils, and erythrocytes. On gross examination, the lobe appears **liver-like**: Red, firm, and airless.

©UWorld

This patient has cough, shortness of breath, fever, and a right lower lobe infiltrate on chest x-ray, indicating **lobar pneumonia** likely due to a community-acquired pathogen (eg, *Streptococcus pneumoniae*). Lobar pneumonia is characterized by a step-wise inflammatory response, as follows:

1. **Congestion** (day 0-2) – Neutrophils respond to bacterial components (eg, peptidoglycan) by releasing cytokines that **increase the permeability** of the pulmonary capillary endothelium, which allows circulating immune cells to more easily migrate to the area. Increased capillary permeability also leads to the accumulation of erythrocytes and **abundant proteinaceous fluid** in the alveolar space, resulting in the affected lobe becoming heavy and red.
2. **Red hepatization** (day 2-4) – The proteinaceous fluid transforms into fibrin strands, resulting in a confluent exudate of fibrin, neutrophils, and erythrocytes. On gross examination, the lobe appears **liver-like**: Red, firm, and airless.
3. **Gray hepatization** (day 4-7) – Red cell disintegration along with increased leukocyte infiltration causes the lung to appear gray rather than red. Neutrophils begin to be replaced by **macrophages** that begin the repair process.
4. **Resolution** (>7 days) – Macrophages secrete digestive enzymes that liquefy the fibrinous exudate, which is reabsorbed, expectorated, or phagocytized by macrophages. The lung parenchyma regains its normal appearance by approximately 3 weeks.

Besides lobar pneumonia, there are 2 other major morphologic categories of pneumonia. **Bronchopneumonia** is an infection of the terminal bronchioles that results in patchy consolidation of a number of lobules. Interstitial pneumonia is an infection of the interstitial tissue of the lung with minimal or no alveolar infiltrate; atypical pneumonias (eg, *Mycoplasma pneumoniae*, *Chlamydia pneumoniae*) are often associated with an interstitial infiltrate.

(Choice A) Cardiogenic pulmonary edema is characterized by the accumulation of fluid in the alveoli due to elevations in hydrostatic pressure within the pulmonary capillaries. Examination often reveals bibasilar crackles and chest x-ray typically shows perihilar alveolar edema with cephalization of the pulmonary vessels.

(Choice B) Asthma is characterized by smooth muscle inflammation of the airways leading to intermittent bronchoconstriction and airflow obstruction. Although cough and shortness of breath can occur during asthma exacerbations, fever and a lobar infiltrate are not typical.

4. **Resolution** (>7 days) – Macrophages secrete digestive enzymes that liquefy the fibrinous exudate, which is reabsorbed, expectorated, or phagocytized by macrophages. The lung parenchyma regains its normal appearance by approximately 3 weeks.

Besides lobar pneumonia, there are 2 other major morphologic categories of pneumonia. **Bronchopneumonia** is an infection of the terminal bronchioles that results in patchy consolidation of a number of lobules. Interstitial pneumonia is an infection of the interstitial tissue of the lung with minimal or no alveolar infiltrate; atypical pneumonias (eg, *Mycoplasma pneumoniae*, *Chlamydia pneumoniae*) are often associated with an interstitial infiltrate.

(Choice A) Cardiogenic pulmonary edema is characterized by the accumulation of fluid in the alveoli due to elevations in hydrostatic pressure within the pulmonary capillaries. Examination often reveals bibasilar crackles and chest x-ray typically shows perihilar alveolar edema with cephalization of the pulmonary vessels.

(Choice B) Asthma is characterized by smooth muscle inflammation of the airways leading to intermittent bronchoconstriction and airflow obstruction. Although cough and shortness of breath can occur during asthma exacerbations, fever and a lobar infiltrate are not typical.

(Choice C) Idiopathic pulmonary fibrosis is associated with pulmonary fibroblast proliferation and extracellular matrix deposition leading to progressive destruction of the pulmonary architecture. Patients typically present with slowly worsening dyspnea, nonproductive cough, and bilateral "Velcro"-sounding crackles. Fever is uncommon and chest x-ray usually reveals increased reticular (interstitial) markings.

(Choice E) Chronic bronchitis is associated with goblet cell metaplasia and inflammation in the large airways. The hypersecretion of mucous can lead to chronic productive cough, dyspnea, and wheezes on examination. Lobar infiltrate is uncommon as the alveoli are not primarily affected.

Educational objective:
Lobar pneumonia is marked by the cytokine-mediated accumulation of neutrophils and proteinaceous material in the alveoli. Over several days, the proteinaceous material becomes fibrinous, neutrophils are replaced by macrophages, and macrophages digest the fibrinous exudate, thereby restoring normal lung histology.

References

- Pathophysiology of community acquired pneumonia.
- Conceptual approaches to lung injury and repair.

Settings

1
2
3
4
5
6
7
8
9
10
11
12
13
14
15
16
17
18

Item 13 of 18
Question Id: 531

Mark | Previous | Next | Full Screen | Tutorial | Lab Values | Notes | Calculator | Reverse Color | Text Zoom | Settings

4. **Resolution** (>7 days) – Macrophages secrete digestive enzymes that liquefy the fibrinous exudate, which is reabsorbed, expectorated, or

Exhibit Display

Zoom In | Zoom Out | Reset | Add To New Card | Existing Card

- Conceptual approaches to lung injury and repair.

Block Time Remaining: 00:00:44
TUTOR

5 | Feedback | Suspend | End Block

Settings

1
2
3
4
5
6
7
8
9
10
11
12
13
14
15
16
17
18

Item 13 of 18
Question Id: 531

Mark | Previous | Next | Full Screen | Tutorial | Lab Values | Notes | Calculator | Reverse Color | Text Zoom | Settings

4. **Resolution** (>7 days) – Macrophages secrete digestive enzymes that liquefy the fibrinous exudate, which is reabsorbed, expectorated, or

Exhibit Display

Zoom In | Zoom Out | Reset | Add To New Card | Existing Card

- Conceptual approaches to lung injury and repair.

Block Time Remaining: 00:00:44
TUTOR

5 | Feedback | Suspend | End Block

Settings

1
2
3
4
5
6
7
8
9
10
11
12
13
14
15
16
17
18

Item 13 of 18
Question Id: 531

Mark | Previous | Next | Full Screen | Tutorial | Lab Values | Notes | Calculator | Reverse Color | Text Zoom | Settings

4. **Resolution** (>7 days) – Macrophages secrete digestive enzymes that liquefy the fibrinous exudate, which is reabsorbed, expectorated, or

Exhibit Display

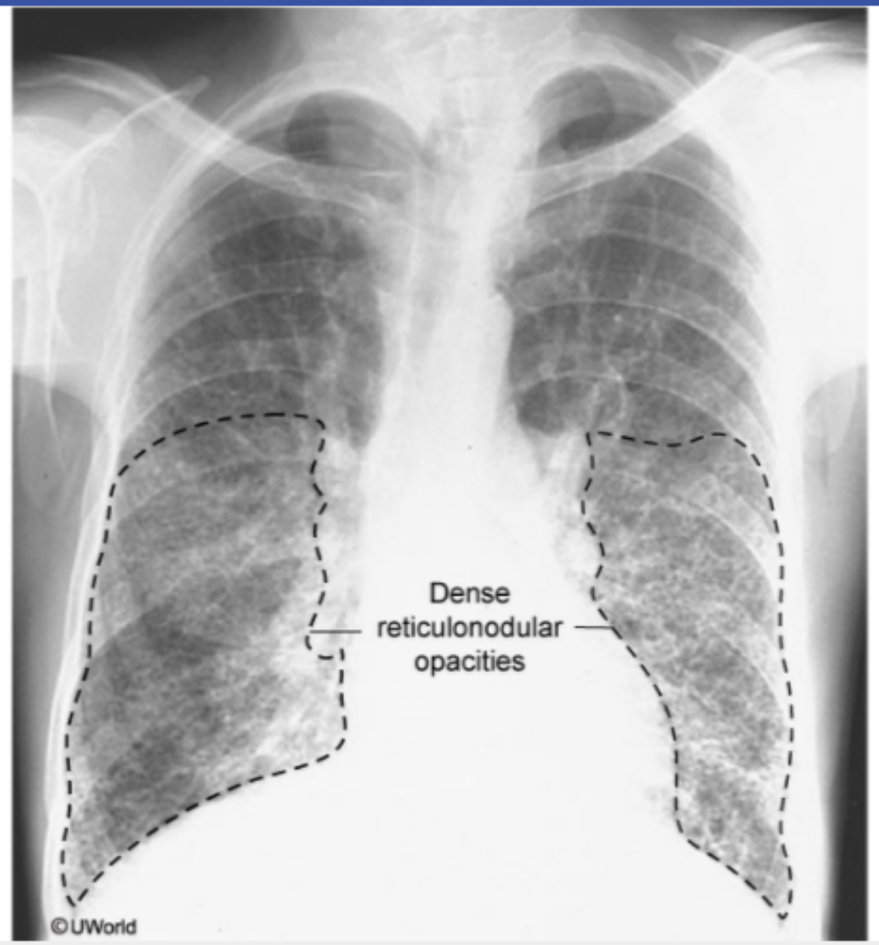

Zoom In | Zoom Out | Reset | Add To New Card | Existing Card

Conceptual approaches to lung injury and repair.

Block Time Remaining: 00:00:44
TUTOR

5 | Feedback | Suspend | End Block

Settings

1
2
3
4
5
6
7
8
9
10
11
12
13
14
15
16
17
18

Item 14 of 18
Question Id: 15485

Mark | Previous | Next | Full Screen | Tutorial | Lab Values | Notes | Calculator | Reverse Color | Text Zoom | Settings

A 35-year-old man comes to the clinic for evaluation of exertional dyspnea and dry cough for 8 months. Oxygen saturation on room air while lying down is 96% and drops to 88% after 6 minutes of walking. Examination shows fine crackles in both lower lungs. Chest x-ray reveals reticular densities in both lung fields. Lung biopsy shows an infiltration of inflammatory cells, predominantly lymphocytes, as well as poorly formed noncaseating granulomas and moderate alveolar septal fibrosis. Which of the following is the most likely diagnosis?

A. Bronchial asthma

B. Chronic bronchitis

C. Hypersensitivity pneumonitis

D. Idiopathic pulmonary fibrosis

E. Pulmonary tuberculosis

Submit

Block Time Remaining: 00:00:44
TUTOR

0 | Feedback | Suspend | End Block

A 35-year-old man comes to the clinic for evaluation of exertional dyspnea and dry cough for 8 months. Oxygen saturation on room air while lying down is 96% and drops to 88% after 6 minutes of walking. Examination shows fine crackles in both lower lungs. Chest x-ray reveals reticular densities in both lung fields. Lung biopsy shows an infiltration of inflammatory cells, predominantly lymphocytes, as well as poorly formed noncaseating granulomas and moderate alveolar septal fibrosis. Which of the following is the most likely diagnosis?

- A. Bronchial asthma (0%)
- B. Chronic bronchitis (2%)
- ✓ C. Hypersensitivity pneumonitis (51%)
- D. Idiopathic pulmonary fibrosis (41%)
- E. Pulmonary tuberculosis (3%)

Omitted
Correct answer
C

51%
Answered correctly

01 sec
Time Spent

07/01/2020
Last Updated

Explanation

Hypersensitivity pneumonitis	
Etiology	• Immunologic response to inhaled antigen (eg, mold, animal protein)
	Acute

Hypersensitivity pneumonitis	
Etiology	• Immunologic response to inhaled antigen (eg, mold, animal protein)
Clinical presentation	**Acute** • Abrupt-onset fever, chills, cough, dyspnea, fatigue, leukocytosis • Episodes often recurrent & self-resolving **Chronic** • Progressive cough, dyspnea, fatigue, weight loss • Hypoxemia that worsens with exertion • Chest x-ray: diffuse reticular interstitial opacities (interstitial fibrosis)
Diagnosis	• PFT: restrictive pattern • BAL: high relative lymphocyte count • Lung biopsy: lymphocytic infiltrate, poorly formed noncaseating granulomas, interstitial fibrosis (chronic only)
Treatment	• Remove antigen exposure (resolves acute disease)

BAL = bronchoalveolar lavage; PFT = pulmonary function testing.

This patient with chronic **dyspnea and cough** accompanied by characteristic lung biopsy findings most likely has **hypersensitivity pneumonitis** (HP). HP is an exaggerated immunologic response to an inhaled antigen; common offending agents include mold, bacteria, animal protein, and chemicals. The condition has variable presentation that is largely dependent on the dose and chronicity of antigen exposure:

- **Acute HP** involves abrupt-onset and often recurring episodes of fever, chills, cough, dyspnea, and fatigue that coincide with intermittent high-dose antigen exposure. Leukocytosis is often present. Chest x-ray may be normal or show scattered micronodular opacification.
- **Chronic HP** involves persistent and **gradually progressive symptoms** (as in this patient) resulting from long-term, moderate-dose antigen

This patient with chronic **dyspnea and cough** accompanied by characteristic lung biopsy findings most likely has **hypersensitivity pneumonitis** (HP). HP is an exaggerated immunologic response to an inhaled antigen; common offending agents include mold, bacteria, animal protein, and chemicals. The condition has variable presentation that is largely dependent on the dose and chronicity of antigen exposure:

- **Acute HP** involves abrupt-onset and often recurring episodes of fever, chills, cough, dyspnea, and fatigue that coincide with intermittent high-dose antigen exposure. Leukocytosis is often present. Chest x-ray may be normal or show scattered micronodular opacification.
- **Chronic HP** involves persistent and **gradually progressive symptoms** (as in this patient) resulting from long-term, moderate-dose antigen exposure. Patients usually have symptoms of cough, dyspnea, fatigue, and **weight loss** for several months or more. Lung auscultation usually reveals **fine crackles**, and chest x-ray shows **interstitial reticular opacities** consistent with the development of pulmonary fibrosis.

The diagnosis of HP can be aided by pulmonary function testing that reveals a **restrictive pattern**; the restriction is worse with chronic HP and is accompanied by more severe impairments in gas exchange (eg, **hypoxemia**, low DLCO). Biopsy in both acute and chronic disease reveals **lymphocytic infiltrate** with poorly formed **noncaseating granulomas** created by the walling off of inhaled antigens. Chronic HP is associated with progressive **alveolar septal fibrosis**. Removal of antigen exposure usually resolves acute disease; however, the fibrosis occurring in chronic disease is often irreversible.

(Choice A) Asthma presents with intermittent cough and dyspnea. Bronchiolar biopsy can reveal noncaseating granulomas, but fibrosis is not typical and eosinophilic infiltrate is expected.

(Choice B) Chronic bronchitis presents with dyspnea and cough and is expected to cause wheezing on lung auscultation. Lymphocytic infiltrate may be present on biopsy, but granulomas are not typical.

(Choice D) Idiopathic pulmonary fibrosis can present quite similarly to chronic HP, but affected patients are usually older (eg, age >50) and granulomas are not expected on lung biopsy.

(Choice E) Pulmonary tuberculosis typically presents with fever, cough, dyspnea, night sweats, and weight loss. Lung biopsy demonstrates lymphocytic infiltrate, but caseating (rather than noncaseating) granulomas.

Educational objective:

Hypersensitivity pneumonitis involves an exaggerated immunologic response to an inhaled antigen and can have an acute or chronic

usually reveals fine crackles, and chest x-ray shows interstitial reticular opacities consistent with the development of pulmonary fibrosis.

The diagnosis of HP can be aided by pulmonary function testing that reveals a **restrictive pattern**; the restriction is worse with chronic HP and is accompanied by more severe impairments in gas exchange (eg, **hypoxemia**, low DLCO). Biopsy in both acute and chronic disease reveals **lymphocytic infiltrate** with poorly formed **noncaseating granulomas** created by the walling off of inhaled antigens. Chronic HP is associated with progressive **alveolar septal fibrosis**. Removal of antigen exposure usually resolves acute disease; however, the fibrosis occurring in chronic disease is often irreversible.

(Choice A) Asthma presents with intermittent cough and dyspnea. Bronchiolar biopsy can reveal noncaseating granulomas, but fibrosis is not typical and eosinophilic infiltrate is expected.

(Choice B) Chronic bronchitis presents with dyspnea and cough and is expected to cause wheezing on lung auscultation. Lymphocytic infiltrate may be present on biopsy, but granulomas are not typical.

(Choice D) Idiopathic pulmonary fibrosis can present quite similarly to chronic HP, but affected patients are usually older (eg, age >50) and granulomas are not expected on lung biopsy.

(Choice E) Pulmonary tuberculosis typically presents with fever, cough, dyspnea, night sweats, and weight loss. Lung biopsy demonstrates lymphocytic infiltrate, but caseating (rather than noncaseating) granulomas.

Educational objective:
Hypersensitivity pneumonitis involves an exaggerated immunologic response to an inhaled antigen and can have an acute or chronic presentation. Chronic disease presents with gradually progressive cough, dyspnea, fatigue, and weight loss, and lung biopsy reveals lymphocytic infiltrate, poorly formed noncaseating granulomas, and septal fibrosis.

References

- Hypersensitivity pneumonitis.

Pathology	Pulmonary & Critical Care	Hypersensitivity pneumonitis
Subject	System	Topic

Settings

1
2
3
4
5
6
7
8
9
10
11
12
13
14
15
16
17
18

Item 15 of 18
Question Id: 484

Mark | Previous | Next | Full Screen | Tutorial | Lab Values | Notes | Calculator | Reverse Color | Text Zoom | Settings

Physiologists conduct a study to identify the protein constituents present in normal pulmonary secretions. They recruit 20 healthy men and women who do not take any medications and have no history of tobacco use. Bronchoalveolar lavage is performed, and the proteins in the fluids are isolated. A specific protein is found that can degrade the elastin present in the extracellular matrix. Which of the following cells are most likely producing this protein?

A. Alveolar macrophages
B. Ciliated epithelium
C. Club cells
D. Goblet cells
E. Type I pneumocytes
F. Type II pneumocytes

Submit

Block Time Remaining: 00:00:45
TUTOR

3 | Feedback | Suspend | End Block

Physiologists conduct a study to identify the protein constituents present in normal pulmonary secretions. They recruit 20 healthy men and women who do not take any medications and have no history of tobacco use. Bronchoalveolar lavage is performed, and the proteins in the fluids are isolated. A specific protein is found that can degrade the elastin present in the extracellular matrix. Which of the following cells are most likely producing this protein?

- ✓ A. Alveolar macrophages (72%)
- B. Ciliated epithelium (1%)
- C. Club cells (8%)
- D. Goblet cells (2%)
- E. Type I pneumocytes (3%)
- F. Type II pneumocytes (12%)

Omitted
Correct answer
A

72%
Answered correctly

02 secs
Time Spent

02/14/2020
Last Updated

Explanation

Proteinase/antiproteinase balance

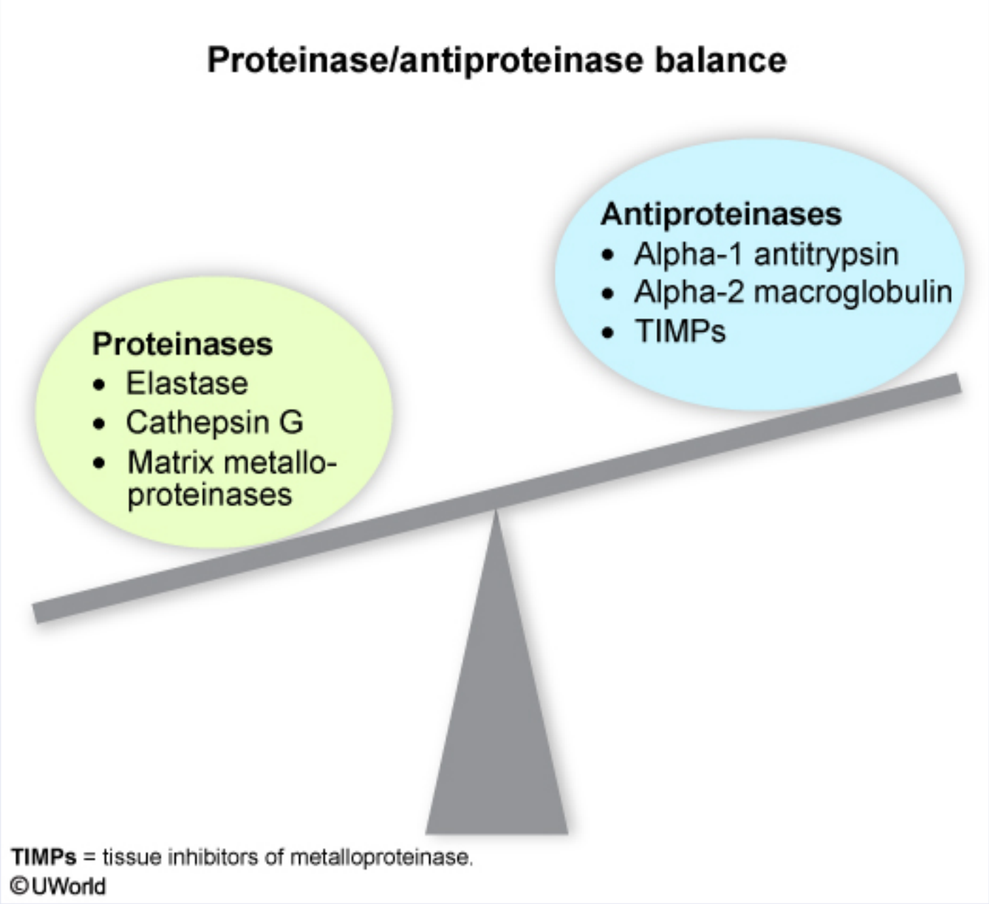

Elastase is a neutral protease contained in **macrophage** lysosomes and in the azurophilic (primary) granules of **neutrophils**. Normally, elastase released from alveolar macrophages and infiltrating neutrophils is balanced by the presence of serum and tissue protease inhibitors. Neutrophil elastase is inhibited by serum alpha-1 antitrypsin, and macrophage elastase is inhibited by tissue inhibitors of metalloproteinases. Neutrophil and macrophage elastases can also degrade each other's (but not their own) inhibitors, augmenting their destructive capacity when both proteases are

©UWorld

Elastase is a neutral protease contained in **macrophage** lysosomes and in the azurophilic (primary) granules of **neutrophils**. Normally, elastase released from alveolar macrophages and infiltrating neutrophils is balanced by the presence of serum and tissue protease inhibitors. Neutrophil elastase is inhibited by serum alpha-1 antitrypsin, and macrophage elastase is inhibited by tissue inhibitors of metalloproteinases. Neutrophil and macrophage elastases can also degrade each other's (but not their own) inhibitors, augmenting their destructive capacity when both proteases are present. **Excess protease activity** is a major contributor to the development of both centriacinar and panacinar **emphysema**.

(Choice B) The ciliated epithelium of the lower respiratory tract sweeps foreign particles and mucus toward the pharynx to promote mucociliary clearance.

(Choice C) Club (formerly Clara) cells are nonciliated cells found predominantly in the terminal portions of the bronchioles. They secrete club cell secretory protein (which protects against airway inflammation and oxidative stress) and surfactant components (which prevent bronchiolar collapse).

(Choice D) Goblet cells secrete mucin to help with mucociliary clearance. They are present in the epithelial lining of the trachea and bronchi but are not present in the more distal airways (ie, terminal bronchioles, respiratory bronchioles, alveoli).

(Choice E) Type I pneumocytes constitute over 95% of the surface area of the alveoli. These end-differentiated squamous cells are not a major source of alveolar fluid secretory products.

(Choice F) Type II pneumocytes secrete the major components of pulmonary surfactant, including phospholipids such as dipalmitoyl phosphatidylcholine and surfactant-associated proteins.

Educational objective:
Alveolar fluid contains neutral proteases (eg, elastases) that are derived from alveolar macrophages and infiltrating neutrophils. These proteases can cause destruction of terminal lung parenchyma (eg, emphysema) when secreted in excess or if left unchecked by deficient antiprotease activity.

References

- Neutrophil elastase contributes to cigarette smoke-induced emphysema in mice.

present. **Excess protease activity** is a major contributor to the development of both centriacinar and panacinar **emphysema**.

(Choice B) The ciliated epithelium of the lower respiratory tract sweeps foreign particles and mucus toward the pharynx to promote mucociliary clearance.

(Choice C) Club (formerly Clara) cells are nonciliated cells found predominantly in the terminal portions of the bronchioles. They secrete club cell secretory protein (which protects against airway inflammation and oxidative stress) and surfactant components (which prevent bronchiolar collapse).

(Choice D) Goblet cells secrete mucin to help with mucociliary clearance. They are present in the epithelial lining of the trachea and bronchi but are not present in the more distal airways (ie, terminal bronchioles, respiratory bronchioles, alveoli).

(Choice E) Type I pneumocytes constitute over 95% of the surface area of the alveoli. These end-differentiated squamous cells are not a major source of alveolar fluid secretory products.

(Choice F) Type II pneumocytes secrete the major components of pulmonary surfactant, including phospholipids such as dipalmitoyl phosphatidylcholine and surfactant-associated proteins.

Educational objective:
Alveolar fluid contains neutral proteases (eg, elastases) that are derived from alveolar macrophages and infiltrating neutrophils. These proteases can cause destruction of terminal lung parenchyma (eg, emphysema) when secreted in excess or if left unchecked by deficient antiprotease activity.

References

- Neutrophil elastase contributes to cigarette smoke-induced emphysema in mice.

Pathology	Pulmonary & Critical Care	Alpha1 antitrypsin deficiency
Subject	System	Topic

Copyright © UWorld. All rights reserved.

A 65-year-old man who recently moved to a new community comes to the physician for a routine health maintenance examination. He has multiple medical problems. The patient has a 20-pack-year smoking history and has consumed 2-3 twelve-ounce bottles of beer daily for the past 20 years. Examination of his joints shows the findings in the image below.

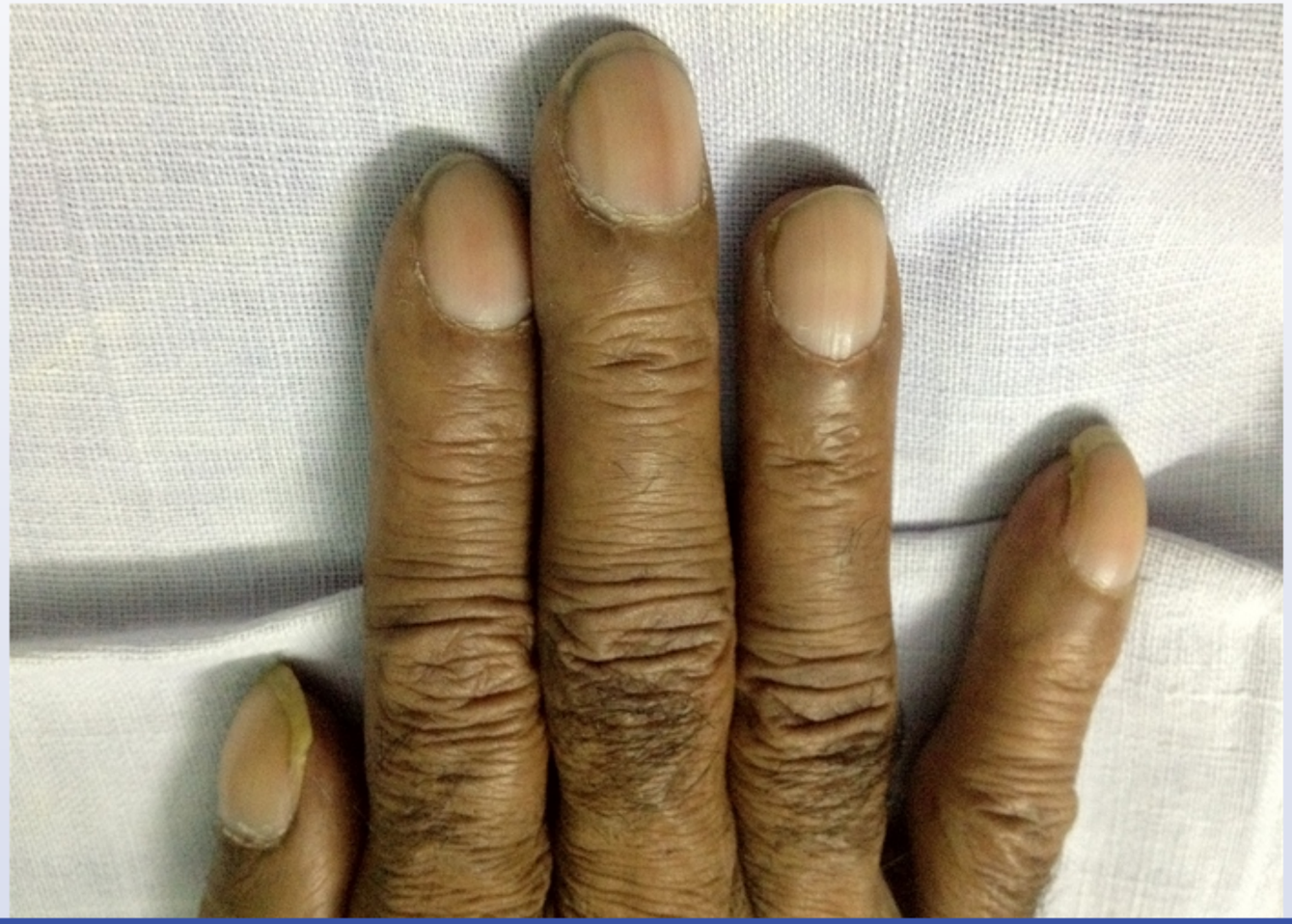

Settings

1
2
3
4
5
6
7
8
9
10
11
12
13
14
15
16
17
18

Item 16 of 18
Question Id: 820

Mark | Previous | Next | Full Screen | Tutorial | Lab Values | Notes | Calculator | Reverse Color | Text Zoom | Settings

Which of the following diseases is most likely to cause this patient's condition?

- A. Rheumatoid arthritis
- B. Bronchial asthma
- C. Bronchiectasis
- D. Mitral valve prolapse
- E. Iron deficiency anemia

Submit

Block Time Remaining: 00:00:50
TUTOR

3 | Feedback | Suspend | End Block

Settings

1
2
3
4
5
6
7
8
9
10
11
12
13
14
15
16
17
18

Item 16 of 18
Question Id: 820

Mark | Previous | Next | Full Screen | Tutorial | Lab Values | Notes | Calculator | Reverse Color | Text Zoom | Settings

Which of the following diseases is most likely to cause this patient's condition?

A. Rheumatoid arthritis (6%)
B. Bronchial asthma (8%)
✓ C. Bronchiectasis (59%)
D. Mitral valve prolapse (6%)
E. Iron deficiency anemia (20%)

Omitted
Correct answer

59%
Answered correctly

04 secs
Time Spent

04/17/2020
Last Updated

Block Time Remaining: 00:00:51
TUTOR

3 | Feedback | Suspend | End Block

Explanation

The image above shows digital clubbing, a thickening of the distal phalanges associated with a number of chronic diseases causing hypoxia. Physical examination usually shows fingers with a "drumstick" appearance, flattening of the nail folds, and shininess of the nail and distal portion of the finger. Pressing on the nails produces a spongy, fluctuant sensation caused by softening of the nail beds.

Clubbing can be primary (idiopathic) or secondary to the following chronic conditions:

Lung diseases: Lung cancer (especially large-cell carcinoma), tuberculosis, cystic fibrosis, bronchiectasis, pulmonary hypertension, empyema, and many other chronic lung diseases associated with hypoxia

Heart diseases: Cyanotic congenital heart diseases (5 Ts, especially tetralogy of Fallot) and bacterial endocarditis

Other: Inflammatory bowel diseases (Crohn's disease, ulcerative colitis), hyperthyroidism, and malabsorption

The pathophysiology of digital clubbing has yet to be completely elucidated. In diseases associated with right-to-left shunts (eg, cyanotic congenital heart disease), it is thought to be caused by a failure of platelet precursors to fragment completely into platelets within the pulmonary circulation. The result is an increase in peripheral circulation of megakaryocytes and platelet clumps. These impact in the fingers and toes and release platelet-derived growth factor and vascular endothelial growth factor (promoters of vascularity). This results in increased fibrovascular proliferation, leading to clubbing of the fingers and toes. Elevated levels of prostaglandin E2 (which activates platelets via the EP3 receptor) have also been implicated in the pathogenesis of digital clubbing.

(Choice A) Swelling of the metacarpophalangeal and proximal (not distal) interphalangeal joints of the hands, along with atrophy of interosseous muscles, is a common finding in patients with rheumatoid arthritis.

(Choice B) Bronchial asthma is not associated with clubbing. Physical examination reveals musical wheezes and possibly signs of other atopic diseases such as atopic dermatitis, nasal polyps, or hives.

(Choice D) Mitral valve prolapse is associated with a midsystolic click and a late systolic murmur best heard over the apex of the heart. It is not

Settings

1
2
3
4
5
6
7
8
9
10
11
12
13
14
15
16
17
18

Item 16 of 18
Question Id: 820

Mark | Previous | Next | Full Screen | Tutorial | Lab Values | Notes | Calculator | Reverse Color | Text Zoom | Settings

Exhibit Display

Zoom In | Zoom Out | Reset | Add To New Card | Existing Card

(Choice D) Mitral valve prolapse is associated with a midsystolic click and a late systolic murmur best heard over the apex of the heart. It is not

Block Time Remaining: 00:00:51
TUTOR

3 | Feedback | Suspend | End Block

Settings

1
2
3
4
5
6
7
8
9
10
11
12
13
14
15
16
17
18

Item 16 of 18
Question Id: 820

Mark | Previous | Next | Full Screen | Tutorial | Lab Values | Notes | Calculator | Reverse Color | Text Zoom | Settings

Exhibit Display

Lesions causing cyanotic congenital heart disease (5 T's)

- Tetralogy of Fallot
- Truncus arteriosus
- Transposition of the great arteries
- Total anomalous pulmonary venous connection
- Tricuspid atresia

© USMLEWorld, LLC

Zoom In | Zoom Out | Reset | Add To New Card | Existing Card

(Choice D) Mitral valve prolapse is associated with a midsystolic click and a late systolic murmur best heard over the apex of the heart. It is not

Block Time Remaining: 00:00:51
TUTOR

3 | Feedback | Suspend | End Block

circulation. The result is an increase in peripheral circulation of megakaryocytes and platelet clumps. These impact in the fingers and toes and release platelet-derived growth factor and vascular endothelial growth factor (promoters of vascularity). This results in increased fibrovascular proliferation, leading to clubbing of the fingers and toes. Elevated levels of prostaglandin E2 (which activates platelets via the EP3 receptor) have also been implicated in the pathogenesis of digital clubbing.

(Choice A) Swelling of the metacarpophalangeal and proximal (not distal) interphalangeal joints of the hands, along with atrophy of interosseous muscles, is a common finding in patients with rheumatoid arthritis.

(Choice B) Bronchial asthma is not associated with clubbing. Physical examination reveals musical wheezes and possibly signs of other atopic diseases such as atopic dermatitis, nasal polyps, or hives.

(Choice D) Mitral valve prolapse is associated with a midsystolic click and a late systolic murmur best heard over the apex of the heart. It is not typically associated with clubbing.

(Choice E) Iron deficiency anemia may result in physical examination findings that include pallor and koilonychia (spoon-shaped nails), but usually not clubbing.

Educational objective:
Digital clubbing is often associated with prolonged hypoxia. It can be found in patients with large-cell lung cancer, tuberculosis, cystic fibrosis, and suppurative lung diseases such as empyema, bronchiectasis, and chronic lung abscesses.

References

- Clubbing: an update on diagnosis, differential diagnosis, pathophysiology, and clinical relevance
- Elevation of Prostaglandin E2 in Lung Cancer Patients with Digital Clubbing

Pathology	Pulmonary & Critical Care	Bronchiectasis
Subject	System	Topic

Copyright © UWorld. All rights reserved.

Settings

1
2
3
4
5
6
7
8
9
10
11
12
13
14
15
16
17
18

Item 17 of 18
Question Id: 795

Mark | Previous | Next | Full Screen | Tutorial | Lab Values | Notes | Calculator | Reverse Color | Text Zoom | Settings

A 35-year-old woman comes to the office due to 3 months of progressive dyspnea on exertion, nonproductive cough, and fatigue. She has a history of seasonal allergies for which she takes over-the-counter antihistamines. The patient ascribes her symptoms to smoking cigarettes and has cut down from a pack to 3 or 4 cigarettes daily. Her mother has rheumatoid arthritis. CT-guided lung biopsy is performed; findings are shown in the image below.

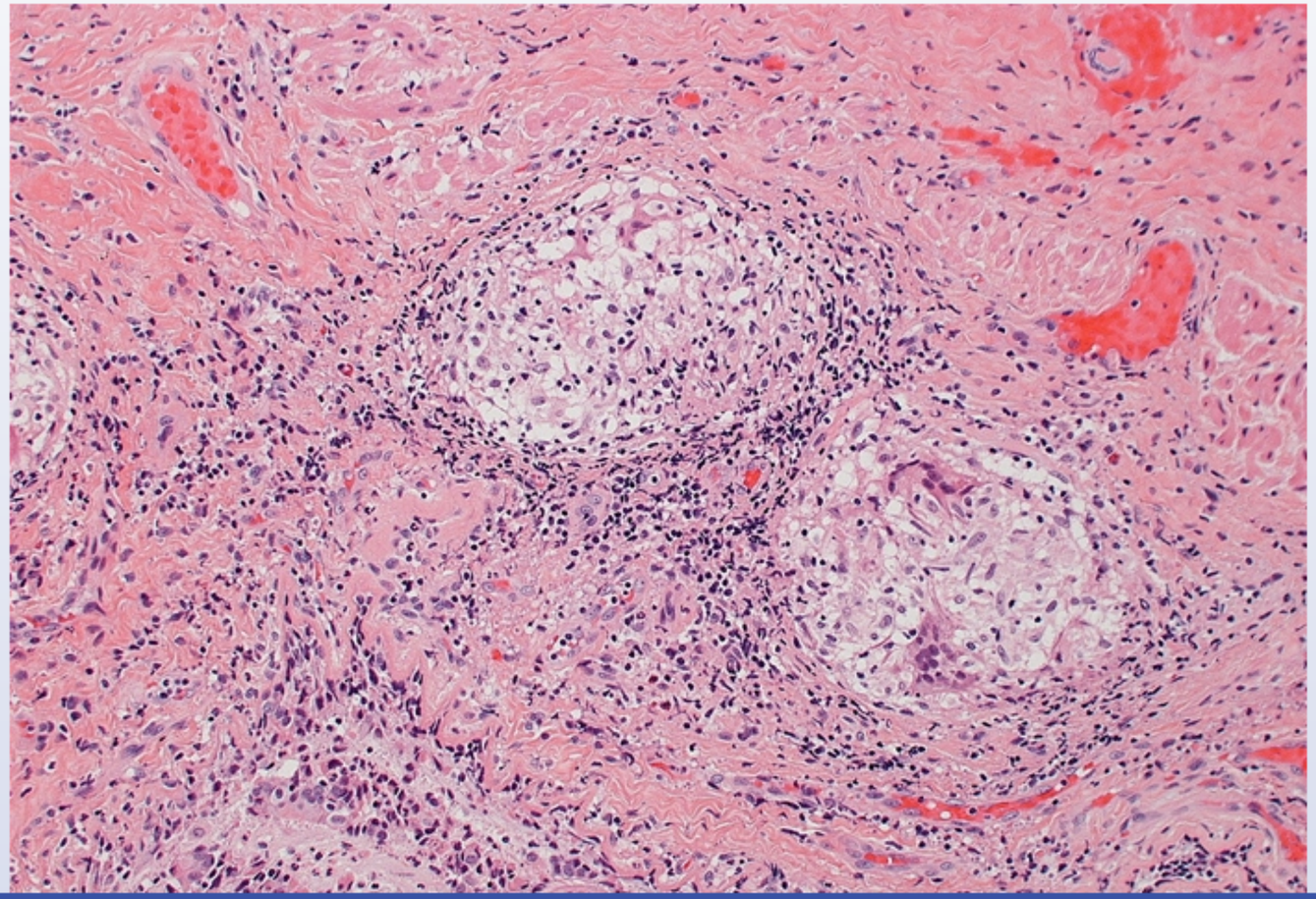

Block Time Remaining: 00:00:52
TUTOR

7 | Feedback | Suspend | End Block

Settings

1
2
3
4
5
6
7
8
9
10
11
12
13
14
15
16
17
18

Item 17 of 18
Question Id: 795

Mark | Previous | Next | Full Screen | Tutorial | Lab Values | Notes | Calculator | Reverse Color | Text Zoom | Settings

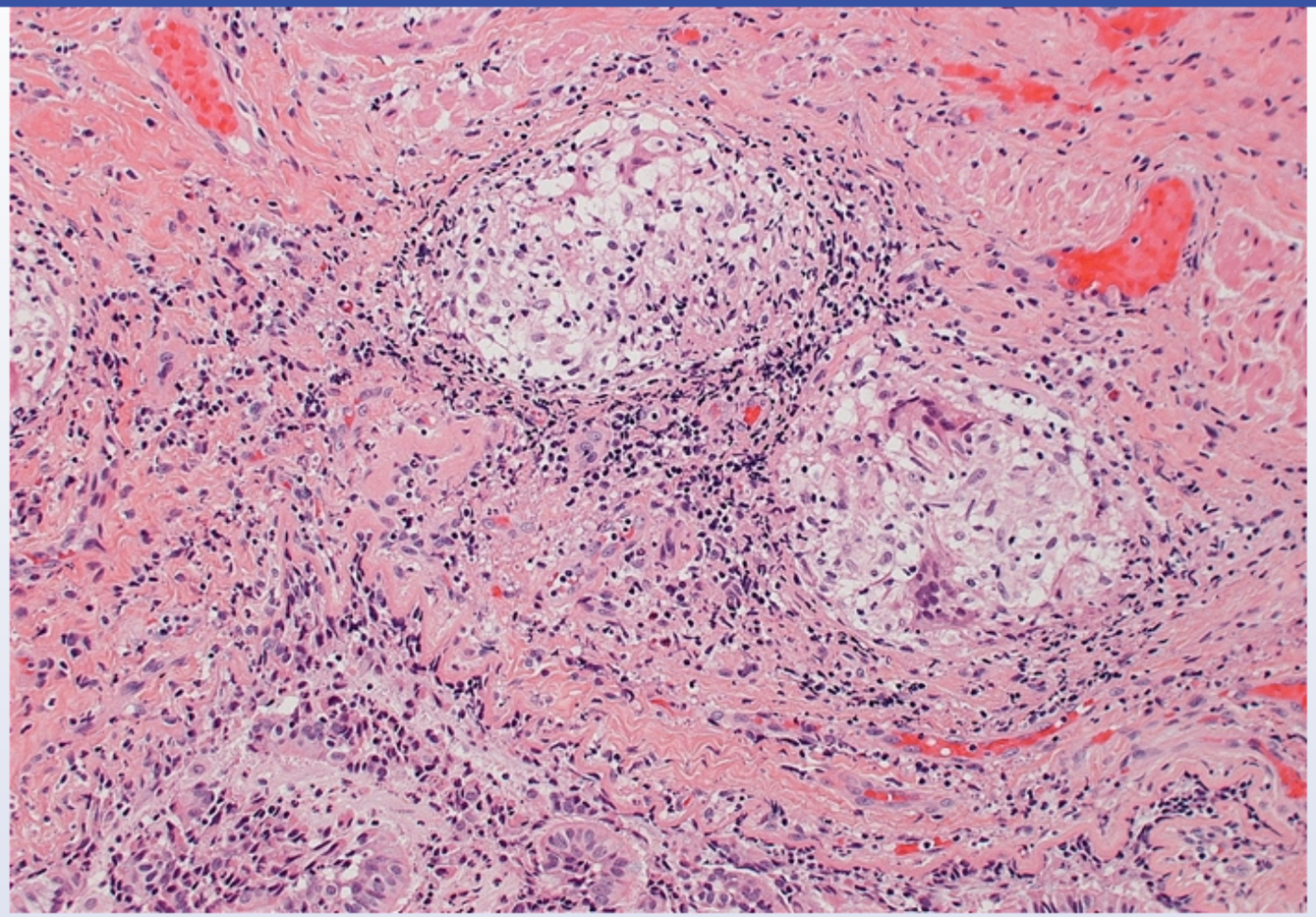

This patient most likely has which of the following conditions?

A. Bronchopulmonary aspergillosis

B. Churg-Strauss syndrome

Block Time Remaining: 00:00:54
TUTOR

7 | Feedback | Suspend | End Block

Settings

1
2
3
4
5
6
7
8
9
10
11
12
13
14
15
16
17
18

Item 17 of 18
Question Id: 795

Mark | Previous | Next | Full Screen | Tutorial | Lab Values | Notes | Calculator | Reverse Color | Text Zoom | Settings

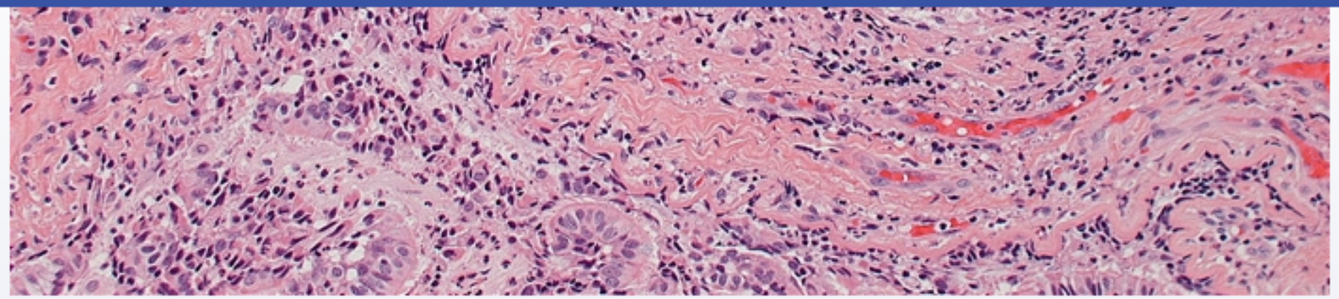

This patient most likely has which of the following conditions?

- A. Bronchopulmonary aspergillosis
- B. Churg-Strauss syndrome
- C. Desquamative interstitial pneumonia
- D. Hodgkin lymphoma
- E. Idiopathic pulmonary fibrosis
- F. Progressive systemic sclerosis
- G. Pulmonary alveolar proteinosis
- H. Sarcoidosis
- I. Small cell lung carcinoma

Submit

Block Time Remaining: 00:00:56
TUTOR

7 | Feedback | Suspend | End Block

Settings

1
2
3
4
5
6
7
8
9
10
11
12
13
14
15
16
17
18

Item 17 of 18
Question Id: 795

Mark | Previous | Next | Full Screen | Tutorial | Lab Values | Notes | Calculator | Reverse Color | Text Zoom | Settings

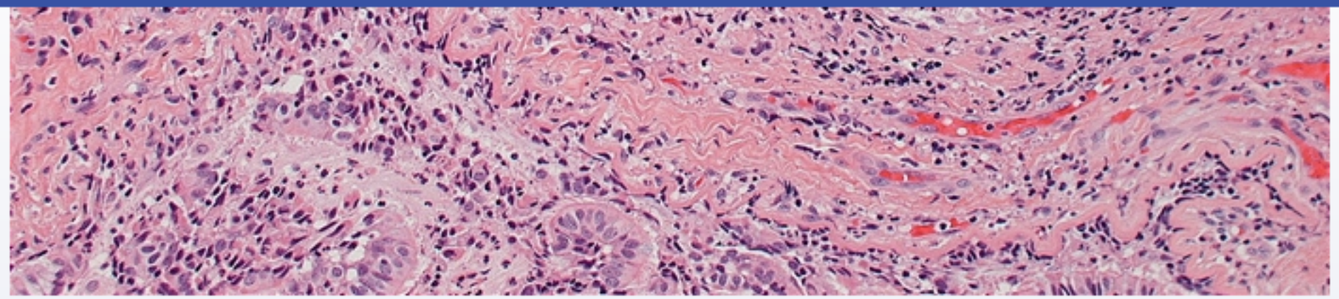

This patient most likely has which of the following conditions?

A. Bronchopulmonary aspergillosis (2%)
B. Churg-Strauss syndrome (9%)
C. Desquamative interstitial pneumonia (1%)
D. Hodgkin lymphoma (0%)
E. Idiopathic pulmonary fibrosis (7%)
F. Progressive systemic sclerosis (2%)
G. Pulmonary alveolar proteinosis (1%)
✓ H. Sarcoidosis (73%)
I. Small cell lung carcinoma (2%)

Omitted
Correct answer

73%
Answered correctly

06 secs
Time Spent

03/03/2020
Last Updated

Block Time Remaining: 00:00:57
TUTOR

7 | Feedback | Suspend | End Block

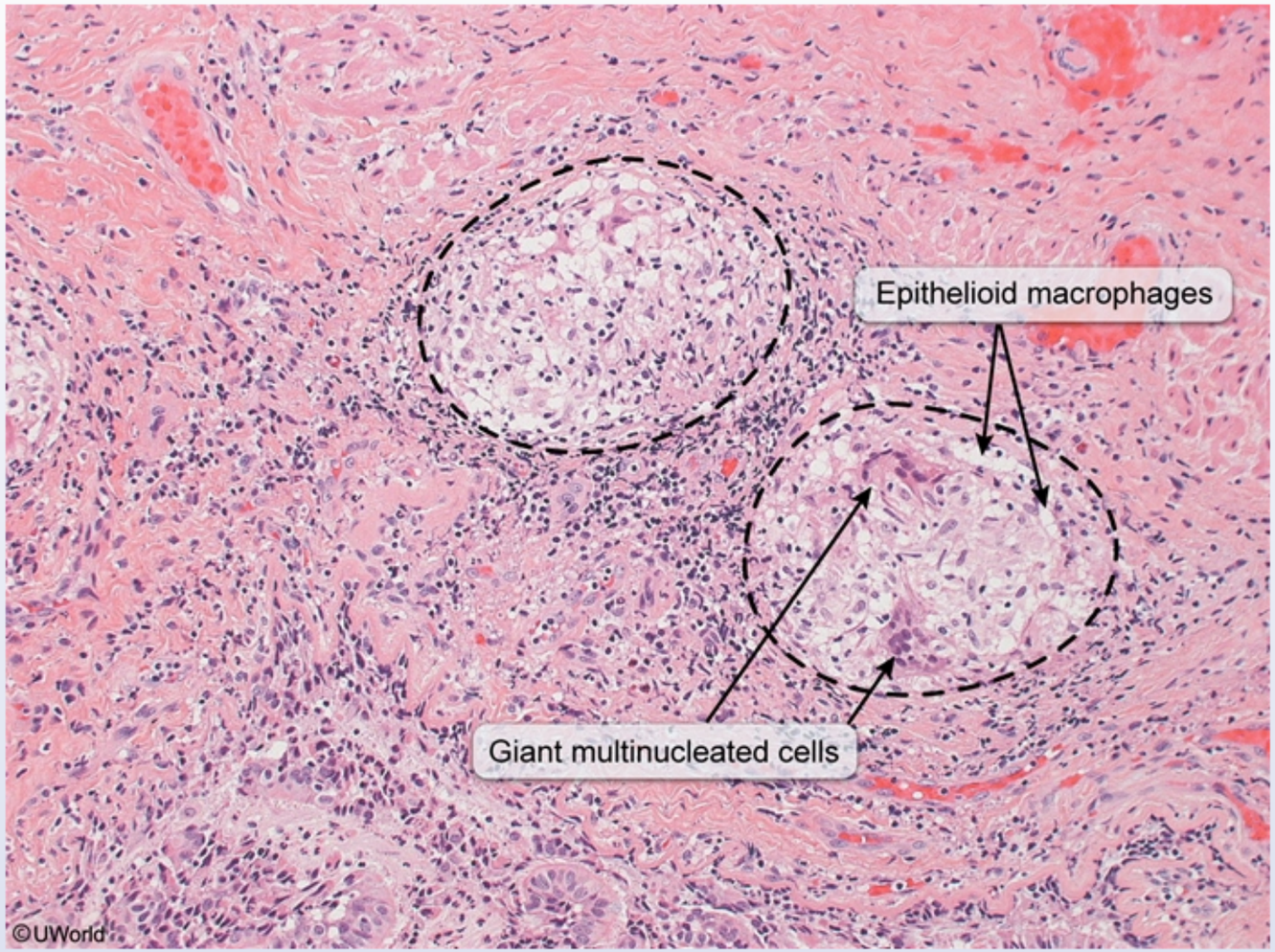

This patient likely has **sarcoidosis**, a chronic multisystem disorder characterized by the formation of **noncaseating granulomas** (eg, epithelioid macrophages, multinucleated giant cells). It typically affects **young adults** and is more prevalent in African Americans and **women**.

Any organ can be affected, but the **lungs** are initially involved in most cases. Patients often present with the insidious onset of respiratory

This patient likely has **sarcoidosis**, a chronic multisystem disorder characterized by the formation of **noncaseating granulomas** (eg, epithelioid macrophages, multinucleated giant cells). It typically affects **young adults** and is more prevalent in African Americans and **women**.

Any organ can be affected, but the **lungs** are initially involved in most cases. Patients often present with the insidious onset of respiratory symptoms (eg, cough, dyspnea, chest pain) accompanied by fatigue, fever, and weight loss. The disease may also be incidentally detected in asymptomatic patients with typical chest x-ray findings (eg, **bilateral hilar lymphadenopathy**, reticular opacities).

(Choice A) Allergic bronchopulmonary aspergillosis typically occurs in patients with asthma or cystic fibrosis and presents with recurrent disease exacerbations . Fungi do not invade the mucosa and noncaseating granulomas would not be seen on microscopy.

(Choice B) Churg-Strauss syndrome (eosinophilic granulomatosis with polyangiitis) usually presents with chronic rhinosinusitis, asthma, and eosinophilia. The granulomas seen with Churg-Strauss syndrome typically have eosinophilic infiltration and extensive necrosis.

(Choices C, E, and G) Desquamative interstitial pneumonia (DIP), idiopathic pulmonary fibrosis (IPF), and pulmonary alveolar proteinosis (PAP) are associated with cigarette smoking and typically present with the insidious onset of progressive dyspnea and chronic cough. However, DIP and IPF are associated with fibrosis and inflammation on biopsy, whereas PAP demonstrates lipoproteinacious material within the alveoli.

(Choice D) Hodgkin lymphoma typically presents with lymphadenopathy and B symptoms (eg, fever, night sweats, weight loss), and histopathology demonstrates Reed-Sternberg cells surrounded by inflammatory cells.

(Choice F) Systemic sclerosis results in progressive collagen deposition and fibrosis of the skin and visceral organs (eg, gastrointestinal tract, lungs, kidneys), which can lead to dyspnea and cough. However, biopsy demonstrates excessive collagen deposition, not granulomas.

(Choice I) Small cell carcinoma is a highly malignant lung cancer that is strongly associated with smoking. Histopathologic features include small cells with scant cytoplasm, granular nuclear chromatin ("salt and pepper" pattern), and indistinct nuclei.

Educational objective:
Sarcoidosis often presents in young African American women with the insidious onset of respiratory symptoms (eg, cough, dyspnea, chest pain) accompanied by fatigue, fever, and weight loss. The characteristic histopathologic feature is noncaseating granulomas, which consist of aggregates of epithelioid macrophages and multinucleated giant cells.

asymptomatic patients with typical chest x-ray findings (eg, **bilateral hilar lymphadenopathy**, reticular opacities).

(Choice A) Allergic bronchopulmonary aspergillosis typically occurs in patients with asthma or cystic fibrosis and presents with recurrent disease exacerbations . Fungi do not invade the mucosa and noncaseating granulomas would not be seen on microscopy.

(Choice B) Churg-Strauss syndrome (eosinophilic granulomatosis with polyangiitis) usually presents with chronic rhinosinusitis, asthma, and eosinophilia. The granulomas seen with Churg-Strauss syndrome typically have eosinophilic infiltration and extensive necrosis.

(Choices C, E, and G) Desquamative interstitial pneumonia (DIP), idiopathic pulmonary fibrosis (IPF), and pulmonary alveolar proteinosis (PAP) are associated with cigarette smoking and typically present with the insidious onset of progressive dyspnea and chronic cough. However, DIP and IPF are associated with fibrosis and inflammation on biopsy, whereas PAP demonstrates lipoproteinacious material within the alveoli.

(Choice D) Hodgkin lymphoma typically presents with lymphadenopathy and B symptoms (eg, fever, night sweats, weight loss), and histopathology demonstrates Reed-Sternberg cells surrounded by inflammatory cells.

(Choice F) Systemic sclerosis results in progressive collagen deposition and fibrosis of the skin and visceral organs (eg, gastrointestinal tract, lungs, kidneys), which can lead to dyspnea and cough. However, biopsy demonstrates excessive collagen deposition, not granulomas.

(Choice I) Small cell carcinoma is a highly malignant lung cancer that is strongly associated with smoking. Histopathologic features include small cells with scant cytoplasm, granular nuclear chromatin ("salt and pepper" pattern), and indistinct nuclei.

Educational objective:
Sarcoidosis often presents in young African American women with the insidious onset of respiratory symptoms (eg, cough, dyspnea, chest pain) accompanied by fatigue, fever, and weight loss. The characteristic histopathologic feature is noncaseating granulomas, which consist of aggregates of epithelioid macrophages and multinucleated giant cells.

Pathology	Pulmonary & Critical Care	Sarcoidosis
Subject	System	Topic

Copyright © UWorld. All rights reserved.

Settings

1
2
3
4
5
6
7
8
9
10
11
12
13
14
15
16
17
18

Item 17 of 18
Question Id: 795

Mark | Previous | Next | Full Screen | Tutorial | Lab Values | Notes | Calculator | Reverse Color | Text Zoom | Settings

asymptomatic patients with typical chest x-ray findings (eg, **bilateral hilar lymphadenopathy**, reticular opacities).

Exhibit Display

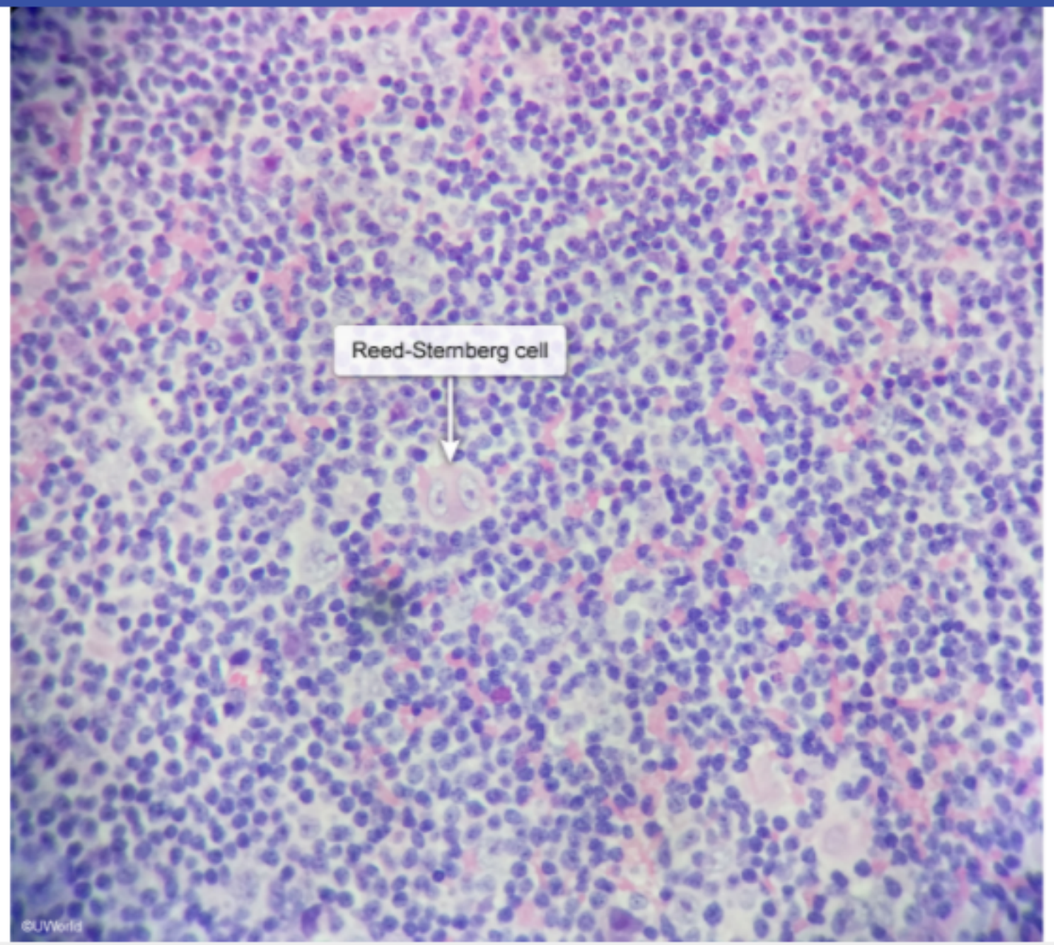

Zoom In | Zoom Out | Reset | Add To New Card | Existing Card

Block Time Remaining: 00:00:57
TUTOR

7 | Feedback | Suspend | End Block

asymptomatic patients with typical chest x-ray findings (eg, **bilateral hilar lymphadenopathy**, reticular opacities).

Exhibit Display

Scleroderma

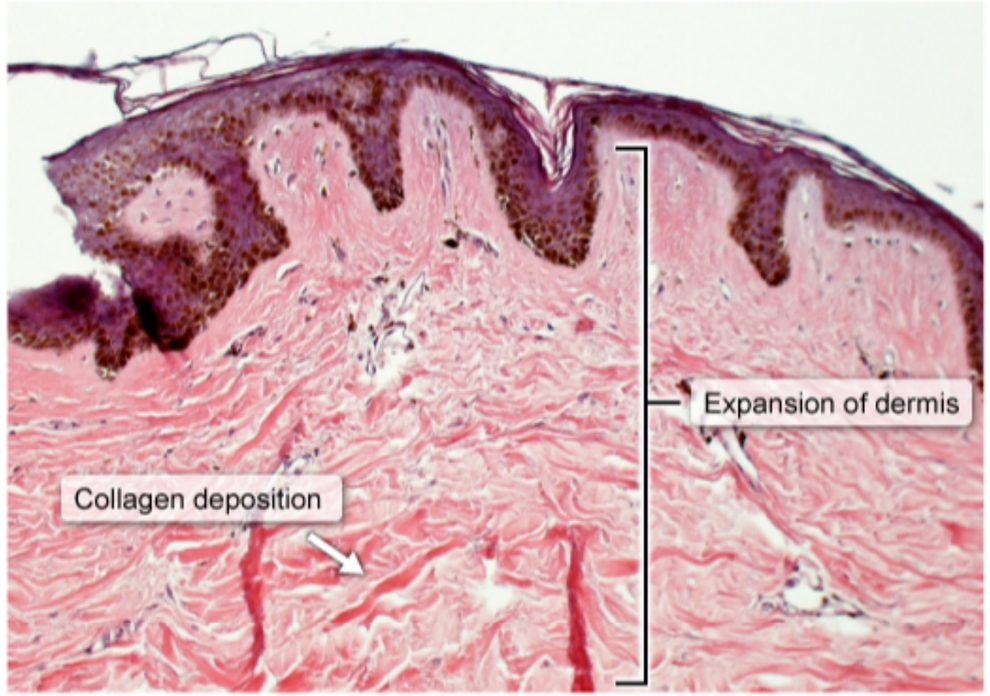

©UWorld

Zoom In | Zoom Out | Reset | Add To New Card | Existing Card

Settings

1
2
3
4
5
6
7
8
9
10
11
12
13
14
15
16
17
18

Item 17 of 18
Question Id: 795

Mark | Previous | Next | Full Screen | Tutorial | Lab Values | Notes | Calculator | Reverse Color | Text Zoom | Settings

asymptomatic patients with typical chest x-ray findings (eg, **bilateral hilar lymphadenopathy**, reticular opacities).

Exhibit Display

Small cell carcinoma Small cell carcinoma

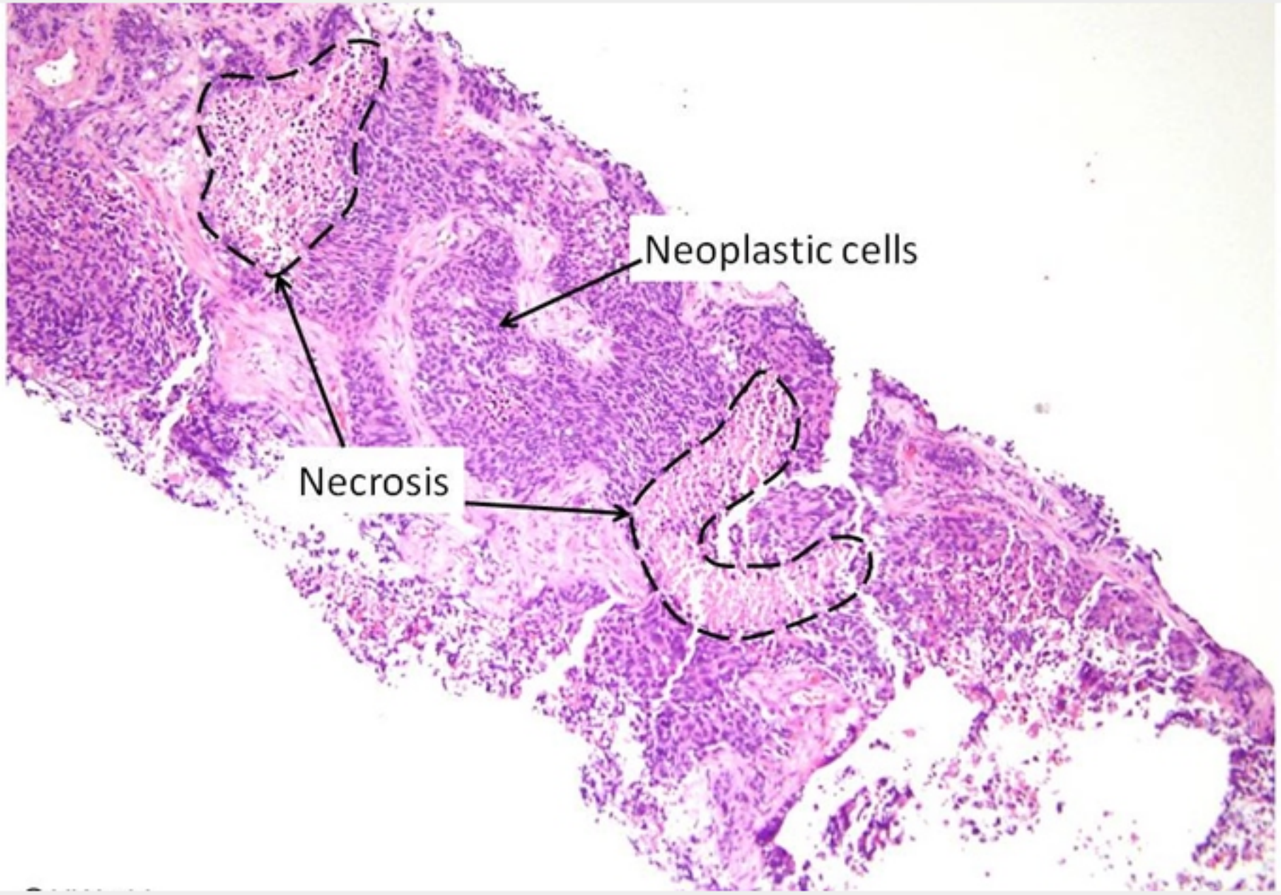

Zoom In | Zoom Out | Reset | Add To New Card | Existing Card

Block Time Remaining: 00:00:57
TUTOR

7 | Feedback | Suspend | End Block

Settings

1
2
3
4
5
6
7
8
9
10
11
12
13
14
15
16
17
18

Item 17 of 18
Question Id: 795

Mark | Previous | Next | Full Screen | Tutorial | Lab Values | Notes | Calculator | Reverse Color | Text Zoom | Settings

asymptomatic patients with typical chest x-ray findings (eg, **bilateral hilar lymphadenopathy**, reticular opacities).

Exhibit Display

Small cell carcinoma Small cell carcinoma

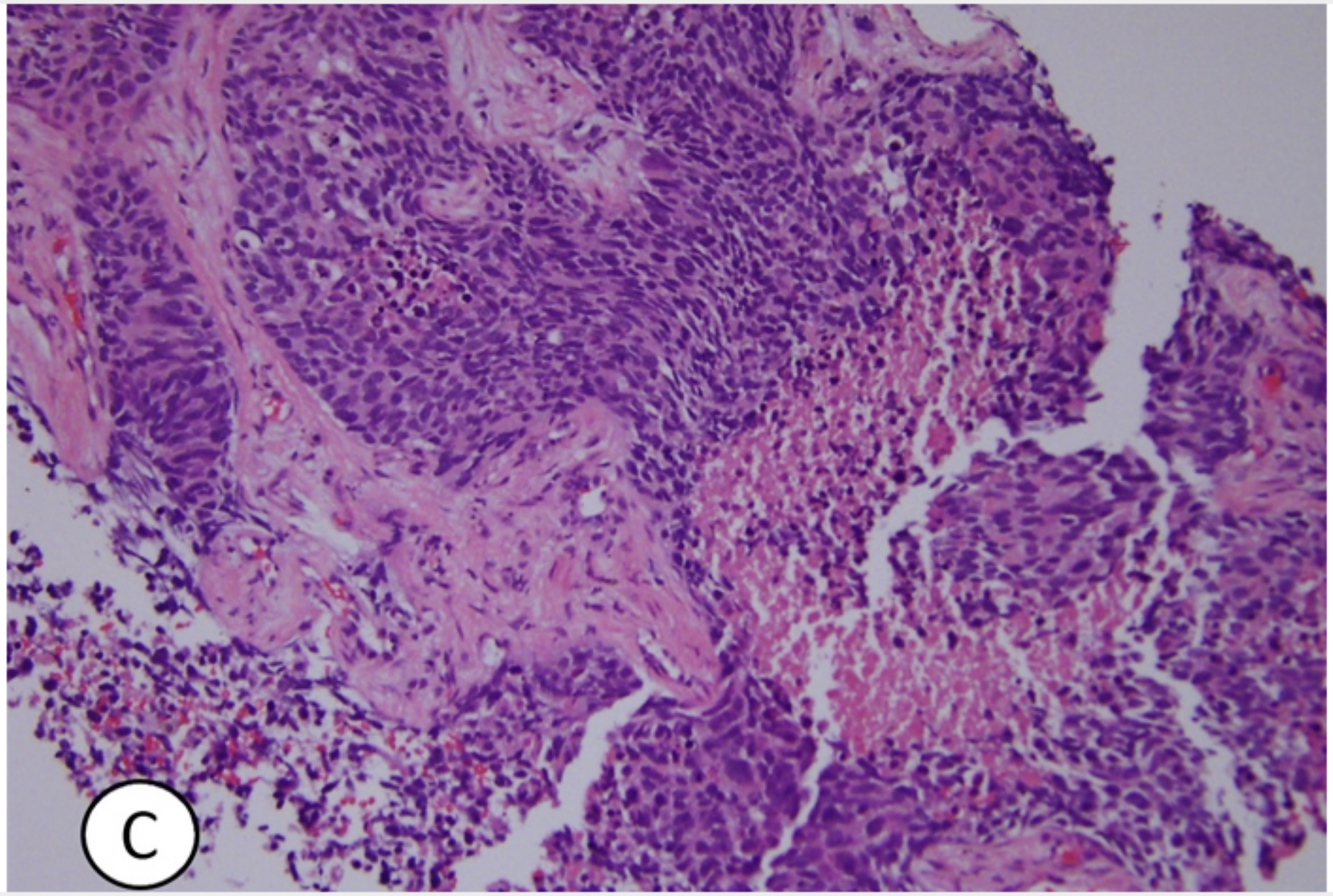

Zoom In | Zoom Out | Reset | Add To New Card | Existing Card

Block Time Remaining: 00:00:57
TUTOR

7 | Feedback | Suspend | End Block

Settings

1
2
3
4
5
6
7
8
9
10
11
12
13
14
15
16
17
18

Item 18 of 18
Question Id: 19244

Mark | Previous | Next | Full Screen | Tutorial | Lab Values | Notes | Calculator | Reverse Color | Text Zoom | Settings

A 36-year-old woman comes to the clinic for evaluation of a 4-month history of nonproductive cough and exertional dyspnea. Her only other medical problem is frequent heartburn, for which she takes over-the-counter antacids. Temperature is 37.1 C (98.8 F), blood pressure is 126/74 mm Hg, pulse is 88/min, and respirations are 20/min. Examination shows bilateral crackles and normal heart sounds. The remainder of the examination is unremarkable. Chest imaging shows bilateral interstitial opacities. Bronchioalveolar lavage reveals >50% of cells being lymphocytes. Which of the following is the most likely diagnosis?

A. Asbestosis
B. Asthma
C. Chronic aspiration
D. Hypersensitivity pneumonitis
E. Pulmonary edema

Submit

Block Time Remaining: 00:00:58
TUTOR

0 | Feedback | Suspend | End Block

A 36-year-old woman comes to the clinic for evaluation of a 4-month history of nonproductive cough and exertional dyspnea. Her only other medical problem is frequent heartburn, for which she takes over-the-counter antacids. Temperature is 37.1 C (98.8 F), blood pressure is 126/74 mm Hg, pulse is 88/min, and respirations are 20/min. Examination shows bilateral crackles and normal heart sounds. The remainder of the examination is unremarkable. Chest imaging shows bilateral interstitial opacities. Bronchioalveolar lavage reveals >50% of cells being lymphocytes. Which of the following is the most likely diagnosis?

- A. Asbestosis (3%)
- B. Asthma (7%)
- C. Chronic aspiration (21%)
- ✓ D. Hypersensitivity pneumonitis (61%)
- E. Pulmonary edema (6%)

Omitted
Correct answer
D

61%
Answered correctly

02 secs
Time Spent

07/01/2020
Last Updated

Explanation

Hypersensitivity pneumonitis	
Etiology	• Immunologic response to inhaled antigen (eg, mold, animal protein)

Hypersensitivity pneumonitis	
Etiology	• Immunologic response to inhaled antigen (eg, mold, animal protein)
Clinical presentation	**Acute** • Abrupt-onset fever, chills, cough, dyspnea, fatigue, leukocytosis • Episodes often recurrent & self-resolving **Chronic** • Progressive cough, dyspnea, fatigue, weight loss • Hypoxemia that worsens with exertion • Chest x-ray: diffuse reticular interstitial opacities (interstitial fibrosis)
Diagnosis	• PFT: restrictive pattern • BAL: high relative lymphocyte count • Lung biopsy: lymphocytic infiltrate, poorly formed noncaseating granulomas, interstitial fibrosis (chronic only)
Treatment	• Remove antigen exposure (resolves acute disease)

BAL = bronchoalveolar lavage; PFT = pulmonary function testing.

This patient with several months of nonproductive cough and exertional dyspnea as well as a **lymphocyte-predominant bronchoalveolar lavage** (BAL) most likely has **hypersensitivity pneumonitis** (HP). HP results from an exaggerated immunologic response that some individuals develop to an **inhaled antigen** (eg, mold, animal protein). Those most commonly affected include farmers (ie, **farmer's lung** due to exposure to moldy hay) and bird keepers (ie, **bird fancier's lung** due to exposure to avian proteins).

The presentation of HP can be acute or chronic. Acute disease usually involves recurrent episodes of abrupt-onset cough, dyspnea, fever, chills, and fatigue that correlate with intermittent antigen exposure. Chronic disease likely results from chronic, long-term antigen exposure, and presents with gradually progressive cough, dyspnea, fatigue, and weight loss over a period of several months. Lung crackles are present with

BAL = bronchoalveolar lavage; PFT = pulmonary function testing.

This patient with several months of nonproductive cough and exertional dyspnea as well as a **lymphocyte-predominant bronchoalveolar lavage** (BAL) most likely has **hypersensitivity pneumonitis** (HP). HP results from an exaggerated immunologic response that some individuals develop to an **inhaled antigen** (eg, mold, animal protein). Those most commonly affected include farmers (ie, **farmer's lung** due to exposure to moldy hay) and bird keepers (ie, **bird fancier's lung** due to exposure to avian proteins).

The presentation of HP can be acute or chronic. Acute disease usually involves recurrent episodes of abrupt-onset cough, dyspnea, fever, chills, and fatigue that correlate with intermittent antigen exposure. Chronic disease likely results from chronic, long-term antigen exposure, and presents with gradually progressive cough, dyspnea, fatigue, and weight loss over a period of several months. Lung crackles are present with both acute and chronic disease. Chest x-ray in acute disease is frequently normal, whereas **diffuse reticular interstitial opacities** are present with **chronic disease** as a network of interstitial inflammation and **fibrosis** develops.

Normally, the leukocytes in alveolar fluid consist of approximately 85% alveolar macrophages, 10% lymphocytes, and a small percentage of neutrophils and eosinophils. With both acute and chronic HP, **BAL usually shows high relative lymphocyte count** (eg, >20%, often >50%), which helps support the diagnosis. Other causes of high relative lymphocyte count in BAL include sarcoidosis, lymphoma, and chronic fungal or mycobacterial infection.

(Choice A) Asbestosis can present with progressive dyspnea and cough, but BAL typically shows increased neutrophils and characteristic asbestos bodies.

(Choice B) Asthma is expected to cause wheezing rather than crackles on lung auscultation. BAL may show increased eosinophils as well as bronchial epithelial cells.

(Choice C) Patients with gastroesophageal reflux disease can have chronic microaspiration, leading to respiratory symptoms (eg, cough, dyspnea). However, BAL typically shows increased neutrophils and characteristic lipid-laden macrophages that result from the aspiration of lipid-containing food or drink.

(Choice E) BAL in cardiogenic pulmonary edema often demonstrates hemosiderin-laden macrophages, resulting from elevated pulmonary capillary hydrostatic pressure leading to extravasation of red blood cells into the alveoli. Leukocyte percentages are not significantly affected.

which helps support the diagnosis. Other causes of high relative lymphocyte count in BAL include sarcoidosis, lymphoma, and chronic fungal or mycobacterial infection.

(Choice A) Asbestosis can present with progressive dyspnea and cough, but BAL typically shows increased neutrophils and characteristic asbestos bodies.

(Choice B) Asthma is expected to cause wheezing rather than crackles on lung auscultation. BAL may show increased eosinophils as well as bronchial epithelial cells.

(Choice C) Patients with gastroesophageal reflux disease can have chronic microaspiration, leading to respiratory symptoms (eg, cough, dyspnea). However, BAL typically shows increased neutrophils and characteristic lipid-laden macrophages that result from the aspiration of lipid-containing food or drink.

(Choice E) BAL in cardiogenic pulmonary edema often demonstrates hemosiderin-laden macrophages, resulting from elevated pulmonary capillary hydrostatic pressure leading to extravasation of red blood cells into the alveoli. Leukocyte percentages are not significantly affected.

Educational objective:
Hypersensitivity pneumonitis results from an exaggerated immunologic response to an inhaled antigen (eg, mold, animal protein), and presents with cough and dyspnea of variable acuity. Bronchoalveolar lavage typically shows high relative lymphocyte count (eg, >20%), which helps support the diagnosis.

References

- An official American Thoracic Society clinical practice guideline: the clinical utility of bronchoalveolar lavage cellular analysis in interstitial lung disease.

Pathology	Pulmonary & Critical Care	Hypersensitivity pneumonitis
Subject	System	Topic

Copyright © UWorld. All rights reserved.